

glossary

OF OSTEOPATHIC TERMINOLOGY

Third Edition

Executive Editor Rebecca Giusti, DO

A / accessory movements / anatomical barrier / anterior component / articular pillar / articulatory technique / **B** / backward torsion / balanced ligamentous tension / biomechanics / **C** / cephalad / cerebrospinal fluid, fluctuation of / cervicolumbar reflex / contraction / **D** / deformation / depressed rib / **E** / effleurage / elastic deformation / elasticity / elevated rib / **F** / facet symmetry / fascial release technique / **G** / gait / lymphatic system / gravitational line / **H** / habituation / hip bone / homeostasis / Hoover technique / **I** / indirect method / innominate somatic dysfunctions / intersegmental motion / **J** / Jones technique / junctional region / **K** / key lesion / kinesthesia / klapping / kyphoscoliosis / **L** / lateroflexion / longitudinal axis / lordosis / lumbolumbar lordotic angle / lymphatic treatment / **M** / manipulation / manual medicine / models of osteopathic care / muscle energy technique / myofascial technique / **N** / neurotrophy / non-allopathic lesion / normalization / nutation / **O** / osteopathic musculoskeletal evaluation / osteopathic postural examination / osteopathic practitioner / osteopathic structural examination / **P** / palpatory skills / passive method / patient cooperation / pedal pump / plasticity / posterior component / **R** / respiratory cooperation / reciprocal inhibition / reflex / **S** / sacral torsion / sagittal plane / scan / scaphoid head / scoliosis / somatic dysfunction / Still technique / **T** / tapotement / tenderpoints / thoracic pump / thrust technique / trigger point / **U** / uncommon compensatory pattern / uncompensated fascial pattern / **V** / velocity / ventral technique / vertebral unit / visceral dysfunction / **W** / weight-bearing line of L3

aacom[®]

AMERICAN ASSOCIATION OF
COLLEGES OF OSTEOPATHIC MEDICINE

A print version of the 2017 *Glossary of Osteopathic Terminology* is available at www.aacom.org/resources/bookstore/Pages/glossary.aspx.

Copies of the Glossary are available for \$15 each.

For larger orders:

1 – 10 copies: \$15 each
11 – 49 copies: \$12 each
50 and up: \$9 each

Payment may be sent by check or money order to:

Publications Orders:
American Association of
Colleges of Osteopathic Medicine
Office of Communications and Marketing
5550 Friendship Blvd.
Suite 310
Chevy Chase, MD 20815

Please note Glossary on your check or money order.

aacom[®]

AMERICAN ASSOCIATION OF
COLLEGES OF OSTEOPATHIC MEDICINE

No part of this publication may be reproduced or transmitted in any form or by any means electronic or mechanical, including photocopying, recording, or by any information storage and retrieval system, without permission in writing from the publisher:

American Association of Colleges
of Osteopathic Medicine
5550 Friendship Blvd.
Suite 310
Chevy Chase, MD 20815

Copyright © 2017

ISBN 978-0-9974411-2-3

Glossary of Osteopathic Terminology

The *Glossary of Osteopathic Terminology* is developed and revised by the Educational Council on Osteopathic Principles (ECOP) of the American Association of Colleges of Osteopathic Medicine (AACOM) Chairman: Kendi Hensel, DO, PhD, of University of North Texas Health Science Center at Fort Worth/Texas College of Osteopathic Medicine. The Glossary Committee is chaired by Rebecca Giusti, DO, of Western University of Health Sciences/ College of Osteopathic Medicine of the Pacific, the Subcommittee Chair Laura Griffin, DO, FAAO of University of Pikeville–Kentucky College of Osteopathic Medicine and Past Committee Chair Walter Ehrenfeuchter, DO, FAAO, of Georgia Campus–Philadelphia College of Osteopathic Medicine and staffed by Tyler Cymet, DO, and Kate Hirsch. Any comments or suggestions should be sent to AACOM Staff Representative Tyler Cymet, DO, at 5550 Friendship Boulevard, Suite 310, Chevy Chase, MD 20815, or by email at MedEd@aacom.org.

The *Glossary of Osteopathic Terminology* first appeared in the *Journal of the American Osteopathic Association* (JAOA) 80:552-567 in April 1981. The 1995 version of the *Glossary of Osteopathic Terminology* was also published in the textbook, *Foundations for Osteopathic Medicine*, Ward RC (ed.) (1997) pp. 1126-1140: Williams & Wilkins, Baltimore, MD, and in *Foundations for Osteopathic Medicine*, Ward.RC (ed.) (2003) pp. 1229-1253: Williams & Wilkins, Baltimore, MD. The most current and revised version is available on the AACOM website at www.aacom.org.

The 2017 *Glossary of Osteopathic Terminology* review was performed by members of ECOP.

Contributing Members

Kendi Hensel, DO, PhD (Chair)
Anthony Will, DO (Vice Chair)
Rebecca Giusti, DO (Secretary)
Ann L. Habenicht, DO, FAAO,
FACOFP (Sergeant-at-Arms)
John Jones, DO, MEd (Historian)
Tyler Cymet, DO (AACOM
Liaison)
Kate Hirsch (AACOM staff)
Lisa R. Chun, DO, MS, FNAOME
Jose Figueroa, DO
Daniel Umberger, DO
David Coffey, DO
Douglas Weston, DO
To Shan Li, DO
Angela Branda, DO
Mark Thai, DO
Susan Miliani, DO
Thomas Fotopoulos, DO
Kelly Halma, DO
Kevin Treffer, DO
Millicent King Channell, DO, FAAO
Stacey Pierce-Talsma, DO
Victoria Troncoso, DO
Lisa DeStefano, DO
William Devine, DO
Heather Ferrill, DO
Robin Dyer, DO

Walter Ehrenfeuchter, DO, FAAO
David Eland, DO, FAAO
John Garlitz, DO
Sharon Gustowski, DO
John Glover, DO, FAAO
Laura Griffin, DO, FAAO
Claire Galin, DO
Shana Shoshy, DO
Deborah Schmidt, DO
Kevin Hayes, DO
David Harden, DO
David Boesler, DO
Kurt Heinking, DO, FAAO
Jan Hendryx, DO, FAAO
James Kribs, DO
Evan Nicholas, DO
Paul Rennie, DO, FAAO
Eric Snider, DO
Stuart Williams, DO

ECOP acknowledges Jonathan Kirsch, DO, and Mark Sandhouse, DO, as well as all previous members for their contribution to the development of the current and past versions of *Glossary of Osteopathic Terminology*.

Purpose

The purpose of this osteopathic glossary is to present important and frequently used words, terms, and phrases that are unique or with special significance to the osteopathic profession. It is not meant to replace a dictionary. The glossary offers the consensus of a large segment of the osteopathic profession and serves to standardize terminology. The ECOP Glossary Review Committee specifically seeks to include those definitions that are uniquely osteopathic in their origin or common usage, distinctive in the osteopathic usage of a common word, and/or important in describing OPP/OMT.

This glossary should be useful to students of osteopathic medicine and helpful to authors and other professionals in understanding and making proper use of osteopathic vocabulary.

Osteopathic treatment methods are a group of techniques that apply a set of distinct unifying principles that guide individualized treatment including high velocity, low amplitude (HVLA), muscle energy, osteopathic cranial manipulative medicine, counterstrain, myofascial release and soft tissue. “Methods” are described as being direct, indirect, or combined. Techniques are specific therapeutic manual procedures such as the Dalrymple pedal pump or the CV-4.

The five models used in discussion of osteopathic patient care are 1) respiratory-circulatory, 2) biomechanical-structural, 3) metabolic-nutritional, 4) neurological, and 5) behavioral-biopsychosocial.

Introduction

Glossary of Osteopathic Terminology

The third edition of the *Glossary of Osteopathic Terminology* (GOT) is an important accomplishment. The work of the Educational Council on Osteopathic Principles (ECOP) which represents the chairs or academic leads from the departments of osteopathic manipulative medicine at each of the colleges of osteopathic medicine is a consensus document that standardizes the words used to discuss osteopathic medicine across the country and the world.

Words matter! While language can evolve, the glossary of osteopathic terminology is a standard brings in the quality of consistency and accuracy when practicing, discussing and assessing students in the field of osteopathic medicine.

Our goal in defining these terms is so that these terms are used correctly and consistently. The other goal is to facilitate communication and to sharpen the accuracy in communication. The definitions here will help people say what they mean by defining the words you need.

In between editions of the Glossary of Osteopathic Terminology, ECOP accepts questions on definitions, proposals of words that need to be defined, or challenges and requests to modify definitions. Those comments can be shared through this site:

https://www.aacom.org/docs/default-source/councils/glossary_guidelines.pdf?sfvrsn=0

We hope you come to depend on the glossary.

TYLER CYMET, DO, FACP, FACOFP

Chief of Clinical Education, AACOM ECOP Staff Liaison

A

accessory joint motions. *See* secondary joint motion.

accessory movements.

Movements used to potentiate, accentuate, or compensate for an impairment in a physiologic motion (e.g., the movements needed to move a paralyzed limb).

accommodation. A self-reversing and non-persistent adaptation.

active motion. *See* motion, active.

acute somatic dysfunction. *See* somatic dysfunction, acute.

adaptation. A responsive alteration or adjustment in the reciprocal relationship between structure and function, by which an individual is able to better accommodate changes in its environment.

allopathy. A therapeutic system in which a disease is treated by producing a second condition that is incompatible with or antagonistic to the first. (*Dorland's*) *See also* allopath, allopathic physician

allopath, allopathic physician.

(1) A term originated by Samuel Hahnemann, MD, to distinguish homeopaths from physicians practicing traditional/orthodox medicine. (2) In common usage a general term used to differentiate MDs (medical doctors) from other schools of medicine.

anatomical barrier. *See* barrier, motion.

angle.

–**ferguson angle.** *See* angle, lumbosacral.

–**lumbolumbar lordotic angle.**

An objective quantification of lumbar lordosis typically determined by measuring the angle between the superior surface of the second lumbar vertebra and the inferior surface of the fifth lumbar vertebra; best measured from a standing lateral x-ray film. (Fig. 1)

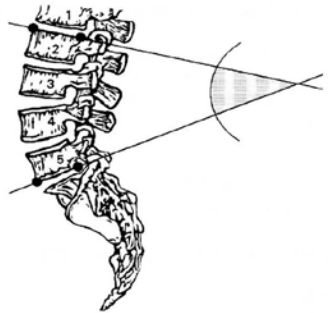


Figure 1. Lumbolumbar angle (L2-L5)

–**lumbosacral angle.** *Also called* Ferguson's angle. Represents the angle of the lumbosacral junction as measured by the inclination of the superior surface of the first sacral vertebra to the horizontal (this is actually a sacral angle); usually measured from

angle (lumbosacral lordotic angle)

standing lateral x-ray films.
(Fig. 2)

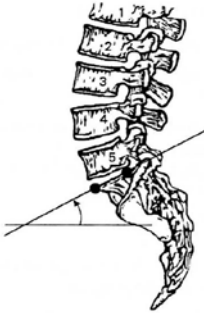


Figure 2. Lumbosacral angle (S1-horizon) (Ferguson's angle).

-lumbosacral lordotic angle.

An objective quantification of lumbar lordosis typically determined by measuring the angle between the superior surface of the second lumbar vertebra and the superior surface of the first sacral segment; best measured from a standing lateral x-ray film. (Fig. 3)

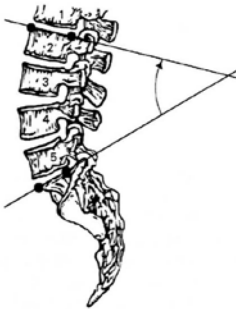


Figure 3. Lumbosacral lordotic angle.

anterior component. A positional descriptor used to identify the side of reference when rotation of a vertebra has occurred; in a condition of right rotation, the left side is the anterior component; usually refers to the less prominent transverse process; *See also* posterior component.

anterior iliac rotation. *See* innominate somatic dysfunction of, anterior innominate rotation.

anterior nutation. *See* nutation.

anterior rib. *See* rib somatic dysfunction; inhaled rib somatic dysfunction.

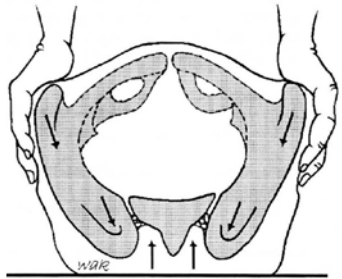


Figure 4. ASIS compression test.

anterior superior iliac spine (ASIS) compression test. *Also called* ASIS ilial compression test. (1) A test for lateralization of somatic dysfunction of the sacrum, innominate, or pubic symphysis. (2) Application of a force through the ASIS into one of the pelvic axes to assess the mechanics of the pelvis. *See also* sacral motion, axis of. (Fig. 4)

articular pillar. (1) Refers to the columnar arrangement of the articular portions of the cervical vertebrae. (2) Those parts of the lateral arches of the cervical vertebrae that contain a superior and inferior articular facet.

articulation. (1) The place of union or junction between two or more bones of the skeleton. (2) The active or passive process of moving a joint through its permitted anatomic range of motion. *See also* osteopathic manipulative treatment method, articularity.

articulatory pop. The sound made when cavitation occurs in a joint. *See also* cavitation.

anterior compression test. *See* anterior superior iliac spine compression test.

ART. *See* osteopathic manipulative treatment, articularity.

articulation. *See* osteopathic manipulative treatment, articularity method (ART).

ASIS compression test. *See* anterior superior iliac spine compression test.

asymmetry. Absence of symmetry of position or motion; dissimilarity in corresponding parts or organs on opposite sides of the body that are normally alike; of particular use when describing position or motion alteration resulting from somatic dysfunction. This term is part

of the *TART* acronym for an osteopathic somatic dysfunction.

axis. (1) An imaginary line about which motion occurs. (2) The second cervical vertebra. (3) One component of an axis system.

axis of rib motion. *See* rib motion, axis of rib motion.

axis of sacral motion. *See* sacral movement axis.

axoplasmic flow. *See* axoplasmic transport.

axoplasmic transport. The antegrade movement of substances from the nerve cell along the axon toward the terminals toward the nerve cell.

B

backward bending. Opposite of forward bending. *See also* extension.

backward bending test. (1) This test discriminates between forward and backward sacral torsion/rotation. (2) This test discriminates between unilateral sacral flexion and unilateral sacral extension.

backward torsion. *See* sacrum, somatic dysfunctions of, backward torsions.

balance point. The position at which the tension within the tissues is symmetrically distributed. *See* neutral.

balance ligamentous tension (BLT)

balanced ligamentous tension (BLT). (1) The precise physiologic point in which the proprioceptive information provided by the ligaments allows the body to equalize the stresses exerted on an articulation in all directions. (2) First described in “Osteopathic Technique of William G. Sutherland, DO” that was published in the *1949 Year Book of Academy of Applied Osteopathy*. See also ligamentous articular strain. See also osteopathic manipulative treatment, balanced ligamentous tension.

balanced membranous tension (BMT). The precise physiologic point in which the proprioceptive information provided by the dural membranes and sutures allows the body to equalize the stresses exerted on those structures in all directions. See also osteopathic manipulative treatment, balanced membranous tension. See also osteopathic cranial manipulative medicine (OCMM).

barrier (motion barrier). The limit to motion; in defining barriers, the palpatory end-feel characteristics are useful. (Fig. 5)

–**anatomic(al) barrier.** The limit of motion imposed by anatomic structure; the limit of passive motion.

–**elastic barrier.** The range between the physiologic and anatomic barrier of motion

in which passive ligamentous stretching occurs before tissue disruption.

–**pathologic barrier.** A restriction of joint motion associated with pathologic change of tissues (example, osteophytes). See also barrier, restrictive barrier.

–**physiologic barrier.** The limit of active motion.

–**restrictive barrier.** A functional limit that abnormally diminishes the normal physiologic range.

batwing deformity. See transitional vertebrae, sacralization.

bind. Palpable resistance to motion of an articulation or tissue. Synonym. resistance. Antonyms. ease, compliance, resilience.

biomechanics. Mechanical principles applied to the study of biological functions; the application of mechanical laws to living structures; the study and knowledge of biological function from an application of mechanical principles.

BLT. See balanced ligamentous tension.

BMT. See balanced membranous tension.

body unity. One of the basic tenets of the osteopathic philosophy; the human being is a dynamic

Concepts Regarding
Joint Motion in a Single Plane

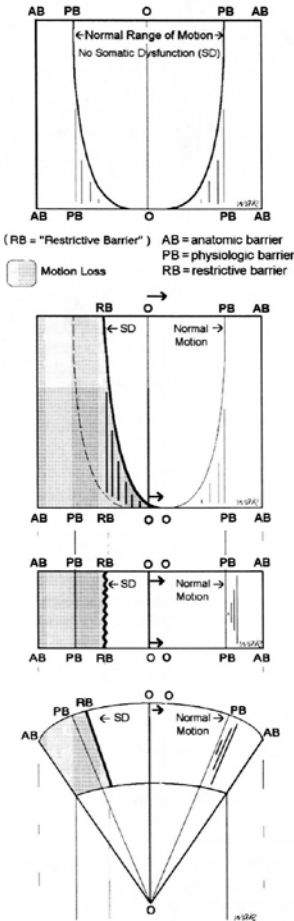


Figure 5. Somatic dysfunction in a single plane: three methods illustrating the "restrictive barrier" (the restrainer): AB, anatomic barrier; PB, physiologic barrier; RB, restrictive barrier; SD, somatic dysfunction (From *Foundations for Osteopathic Medicine*, Baltimore, Williams & Wilkins, 1997:484.)

unit of function; *See also* osteopathic philosophy.

bogginess. A tissue texture abnormality characterized principally by a palpable sense of sponginess in the tissue, interpreted as resulting from congestion due to increased fluid content.

bucket handle rib motion. *See* rib motion, bucket handle.

C

caliper rib motion. *See* rib motion, caliper rib motion.

caudad. Toward the tail or inferiorly.

caught in exhalation. *See* rib somatic dysfunction, exhaled rib dysfunction.

caught in inhalation. *See* rib somatic dysfunction, inhaled rib dysfunction.

cavitation. The formation of small vapor and gas bubbles within fluid caused by local reduction in pressure. This phenomenon is believed to produce an audible "pop" in certain forms of osteopathic medical treatment.

CCP. *See* fascial patterns, common compensatory pattern.

cephalad. Toward the head.

cephalad pubic dysfunction. *See* pubic bone, somatic dysfunctions of, superior pubic shear.

cerebrospinal fluid, fluctuation of.

A description of the hypothesized action of cerebrospinal fluid with regard to the craniosacral mechanism.

Certification in Neuromusculoskeletal Medicine and Osteopathic Manipulative Medicine (C-NMM/OMM).

Certification is granted by the American Osteopathic Association (AOA) through the American Osteopathic Board of Neuromusculoskeletal Medicine (AOBNMM). First granted in 1999. *See also* Neuromusculoskeletal Medicine (NMM).

Certification in Special Proficiency in Osteopathic Manipulative Medicine (C-SPOMM).

Specialty board Certification in Osteopathic Manipulative Medicine prior to 1999. A certification granted by the American Osteopathic Association through the American Osteopathic Board of Special Proficiency in OMM. Replaced by C-NMM/OMM in that year. *See also* C-NMM/OMM.

cervicolumbar reflex. *See* reflex, cervicolumbar.

Chapman reflex. (1) A group of palpable points occurring in predictable locations on the anterior and posterior surfaces of the body that are considered to be reflections of visceral dysfunction or disease (2) Originally used by Frank

Chapman, DO, and described by Charles Owens, DO.

chronic somatic dysfunction. *See* somatic dysfunction, chronic somatic dysfunction.

circumduction. (1) The circular movement of a limb. (2) The rotary movement by which a structure is made to describe a cone, the apex of the cone being a fixed point (e.g., the circular movement of the shoulder).

C-NMM/OMM. *See* Certification in Neuromusculoskeletal Medicine and Osteopathic Manipulative Medicine.

combined technique. *See* osteopathic manipulative treatment, combined treatment method.

common compensatory pattern. *See* fascial patterns, common compensatory pattern.

compensation. A process in which there is an adaptive response to any alteration of structure or function in an attempt to optimize health.

complete motor asymmetry. Asymmetry of palpatory responses to all regional motion inputs including rotation, translation, and active respiration.

compliance. (1) The ease with which a tissue may be deformed. (2) Direction of ease in motion testing.

compression. (1) Somatic dysfunction in which two

structures are forced together.
(2) A force that approximates two structures.

compression of the fourth ventricle (CV-4). *See* osteopathic manipulative treatment, (CV-4). *See also* osteopathic cranial manipulative medicine.

conditioned reflex. *See* reflex, conditioned.

contraction. Shortening and/or development of tension in muscle.

–**concentric contraction.**

Contraction of muscle resulting in approximation of attachments.

–**eccentric contraction.**

Lengthening of muscle during contraction due to an external force.

–**isokinetic contraction.** (1) A concentric contraction against resistance in which the angular change of joint motion is at the same rate. (2) The counterforce is less than the patient force.

–**isolytic contraction.** (1) A form of eccentric contraction designed to break adhesions using an operator-induced force to lengthen the muscle. (2) The counterforce is greater than the patient force.

–**isometric contraction.** (1) Change in the tension of a muscle without approximation of muscle origin and insertion. (2) Operator force equal to patient force.

–**isotonic contraction.** (1) A form of concentric contraction

in which a constant force is applied. (2) Operator force less than patient force.

contracted muscle. The physiologic response to a neuromuscular excitation. *See also* contracted muscle.

contractured muscle.

Histological change substituting non-contractile tissue for muscle tissue, which prevents the muscle from reaching normal relaxed length. *See also* contracted muscle.

core link. The connection of the spinal dura mater from the occiput at the foramen magnum to the sacrum. It coordinates the synchronous motion of these two structures.

coronal plane. *See* plane, coronal plane.

costal dysfunction. *See* rib, somatic dysfunction.

counternutation. Posterior movement of the sacral base around a transverse axis in relation to the ilia. *See also* nutation.

counterstrain technique. *See* osteopathic manipulative treatment, counterstrain.

counterstrain point. (1) A discrete area of tissue texture abnormality which often exhibits tenderness and responds to a positional release technique. (2) Points used in counterstrain technique developed by Lawrence Jones, DO. *See also* tenderpoints. *See also* osteopathic manipulative treatment, counterstrain.

cranial manipulation.

See osteopathic cranial manipulative medicine. See also osteopathic manipulative treatment method, osteopathic cranial manipulative medicine.

cranial rhythmic impulse Also called CRI. (1) A rhythmic

fluctuation palpable throughout the entire body believed to be synchronous with the primary respiratory mechanism. (2) Term coined by John Woods, DO, and Rachel Woods, DO.

cranial technique. See osteopathic manipulative treatment, osteopathic cranial manipulative medicine. See also primary respiratory mechanism.

cranosacral manipulation.

See osteopathic manipulative treatment, osteopathic cranial manipulative medicine.

cranosacral mechanism.

(1) A term used to refer to the anatomical connection between the occiput and the sacrum by the spinal dura mater. (2) A term coined by William G. Sutherland, DO. See extension, sacral. See also flexion. See also primary respiratory mechanism.

creep. The capacity of fascia and other tissue to lengthen when subjected to a constant tension load resulting in less resistance to a second load application.

C-SPOMM. See Certification in Special Proficiency in Osteopathic Manipulative Medicine.

CV-4. See osteopathic manipulative treatment, compression of the fourth ventricle (CV-4).

D

Dalrymple treatment. See osteopathic manipulative treatment, pedal pump.

decompensation. A dysfunctional, persistent pattern, in some cases reversible, resulting when homeostatic mechanisms are partially or totally overwhelmed.

deformation.

–**plastic deformation.** A non-recoverable deformation. See also elastic deformation.

–**elastic deformation.** Any recoverable deformation. See also plastic deformation.

depressed rib. See rib somatic dysfunction, exhaled rib dysfunction. See also exhaled rib dysfunction.

dermatome. (1) The area of skin supplied by cutaneous branches from a single spinal nerve. (Neighboring dermatomes may overlap) (2) Cutis plate; the dorsolateral part of an embryonic somite. (Fig. 6 and Fig. 7)

diagnostic palpation. See palpatory diagnosis.

diagonal axis. See sacral movement axis, oblique axis (diagonal).

direct method (technique).

See osteopathic manipulative treatment, direct treatment.

DO. (1) Doctor of Osteopathy (graduate of a school accredited by the American Osteopathic Association Commission on Osteopathic College Accreditation [COCA]). (2) Doctor of Osteopathic Medicine (graduate of a school

accredited by the American Osteopathic Association-COCA). (3) Diplomate in Osteopathy (the first degree granted by American School of Osteopathy). (4) Diplomate of Osteopathy, a degree granted by some schools of osteopathy outside the United States (not accredited by the American Osteopathic Association-COCA).

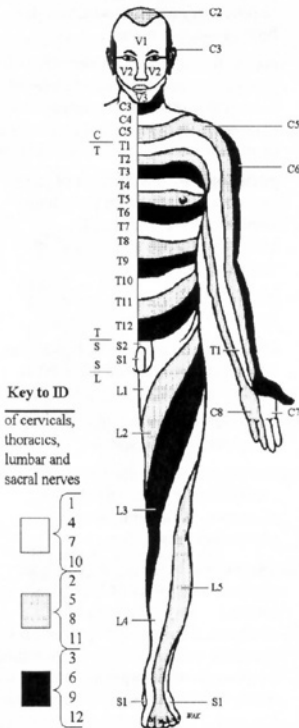


Figure 6. Dermatomal map (anterior). (Modified from Agur AMR, *Grant's Atlas of Anatomy*, 9th ed. Baltimore, Md: Williams & Wilkins; 1991:37).

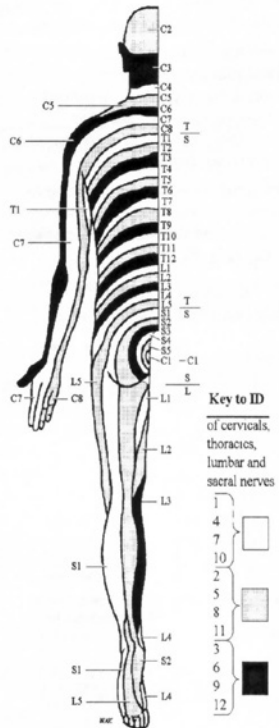


Figure 7. Dermatomal map (posterior). (Modified from Agur AMR, *Grant's Atlas of Anatomy*, 9th ed. Baltimore, Md: Williams & Wilkins; 1991:37).

E

ease. Relative palpable freedom of motion of an articulation or tissue. Synonyms. compliance, resilience. Antonyms. bind, resistance.

easy normal. *See* neutral, definition #2.

-ed. A suffix describing status, position, or condition (e.g., extended, flexed, rotated, restricted).

ECOP. *See* Educational Council on Osteopathic Principles.

Educational Council on Osteopathic Principles (ECOP).

A component group of the American Association of Colleges of Osteopathic Medicine (AACOM). The council is composed of one representative from each osteopathic medical school who oversee the teaching of osteopathic principles and practice, including osteopathic manipulative treatment at each institution.

effleurage. Stroking movement used to move fluids.

elastic deformation. *See* deformation, elastic.

elasticity. Ability of a strained body or tissue to recover its original shape after deformation. *See also* plasticity; viscosity.

elevated rib. *See* rib somatic dysfunction, inhalation rib dysfunction. *See also* rib motion, exhalation rib restriction.

end feel. Perceived quality of motion as an anatomic or physiologic restrictive barrier is approached.

enthesitis. (1) Traumatic disease occurring at the insertion of muscles where recurring concentration of muscle stress provokes inflammation with a strong tendency toward fibrosis and calcification. (2) Inflammation of the muscular or tendinous attachment to bone.

ERS. A descriptor of spinal somatic dysfunction used to denote a combination extended (E), rotated (R), and sidebent (S) vertebral position.

–ERS left. Somatic dysfunction in which the vertebral unit is extended, rotated and sidebent left; usually preceded by a designation of the vertebral unit(s) involved (e.g., T5 ERS left or T5 ERLSL).

–ERS right. Somatic dysfunction in which the vertebral unit is extended, rotated and sidebent right; usually preceded by a designation of the vertebral unit(s) involved (e.g., C3-5 ERS right or C3-5 ERRSR).

exaggeration treatment method. *See* osteopathic manipulative treatment, exaggeration.

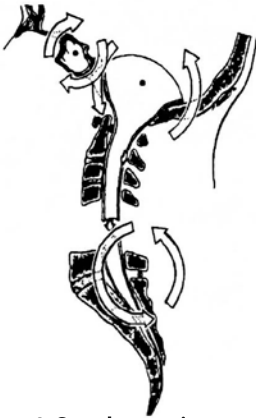

Figure 8. Sacral extension.
Osteopathic Cranial Manipulative
Medicine



Figure 9. Regional extension.

exaggeration technique. *See* osteopathic manipulative treatment, exaggeration technique.

exhalation rib dysfunction. *See* rib somatic dysfunction, exhalation rib dysfunction.

exhalation rib restriction. *See* rib somatic dysfunction, inhaled rib dysfunction.

exhaled rib. Historic term, using positional (static) diagnosis. *See* rib somatic dysfunction, inhaled somatic dysfunction.

extension. (1) Accepted universal term for backward motion of the spine in the sagittal plane about a transverse axis; in a vertebral unit when the superior part moves backward. (2) In extremities, it is the straightening of a curve or angle (biomechanics). (3) Historic term, separation of the ends of a curve in a spinal region.

–**regional extension.** *Also called* Fryette’s regional extension (Fig. 9). Historically, the straightening in the sagittal plane of a spinal region.

–**sacral extension.** (1) Posterior movement of the base of the sacrum in relation to the ilia (Fig. 10). *See also* flexion, sacral.

extrinsic corrective forces.

Treatment forces external to the patient that may include operator effort, effect of gravity, mechanical tables, etc. *See also* intrinsic corrective forces.

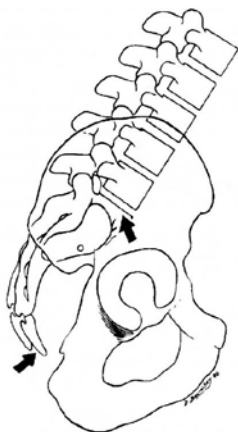


Figure 10. Sacral extension.

F

FAAO. See Fellow of American Academy of Osteopathy

facet asymmetry. Configuration in which the structure, position, and/or motion of the facets are not equal bilaterally. See also facet symmetry; tropism, facet.

facet symmetry. Configuration in which the structure, position, and/or motion of the facets are equal bilaterally. See also facet asymmetry; symmetry.

facilitated positional release. See osteopathic manipulative treatment, facilitated positional release.

facilitated segment. See spinal facilitation.

facilitation. See spinal facilitation.

fascial patterns. (1) Systems for classifying and recording the preferred directions of fascial motion throughout the body. (2) Based on the observations of J. Gordon Zink, DO, and W. Neidner, DO.

–**common compensatory pattern (CCP).** The specific finding of alternating fascial motion preference at transitional regions of the body described by Zink and Neidner. (Fig. 11)

–**uncommon compensatory pattern.** The finding of alternating fascial motion preference in the direction opposite that of the common compensatory pattern described by Zink and Neidner. (Fig. 12)

–**uncompensated fascial pattern.** The finding of fascial preferences that do not demonstrate alternating patterns of findings at transitional regions. Clinically this generally occurs following postural stress or trauma and is frequently associated with development of symptomatology.

fascial release technique. See osteopathic manipulative treatment, myofascial release.

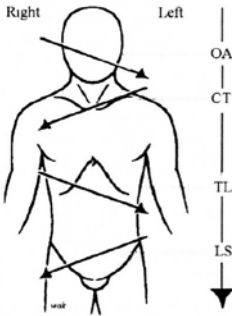


Figure 11. Common compensatory fascial pattern (Zink).

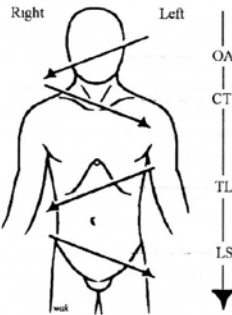


Figure 12. Uncommon compensatory fascial pattern (Zink).

fascial unwinding. See osteopathic manipulative treatment, fascial unwinding.

Fellow of American Academy of Osteopathy (FAAO). This earned post-doctoral fellowship is conferred by the American Academy of Osteopathy. Those who earn the FAAO must demonstrate their commitment

to osteopathic principles and practice through teaching, writing, and service, performed at the highest level of professional and ethical standards.

Ferguson angle. See angle, lumbosacral.

flexion. Also called Fryette's regional flexion. (1) Accepted universal term for forward motion of the spine, in its sagittal plane about a transverse axis, where the superior part moves forward. (2) In the extremities, it is the approximation of a curve or angle (biomechanics). (3) In osteopathic cranial manipulative medicine, flexion is said to occur when the sacral base moves postero-superiorly as the sphenobasilar synchondrosis (SBS) ascends and angulates during the inhalation phase of the primary respiratory mechanism. (Fig. 13) (4) Approximation of the ends of a curve in a spinal region. See flexion, regional flexion.

–**regional flexion.** Also called Fryette's regional flexion. Historically, is the approximation of the ends of a curve in the sagittal plane of the spine. See flexion. (Fig. 14)

–**sacral flexion.** Anterior movement of sacral base in relation to the ilia. (Fig. 15) See also extension, sacral extension.

–**flexion left.** *See* sidebending.

–**flexion right.** *See* sidebending.

flexion tests. Tests for iliosacral or sacroiliac somatic dysfunction.

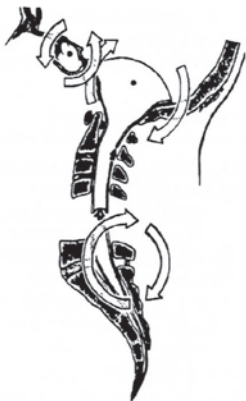


Figure 13. Sacral flexion (Osteopathic Cranial Manipulative Medicine)

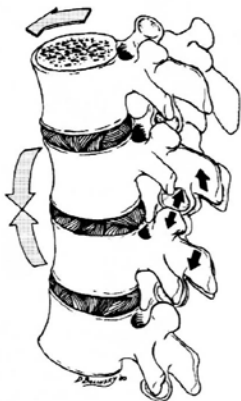

Figure 14. Regional flexion.

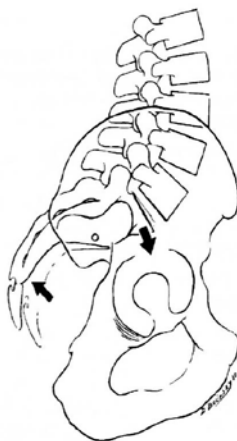


Figure 15. Sacral flexion.

–**seated flexion test.** A screening test that determines the side of sacroiliac somatic dysfunction (motion of the sacrum on the ilium).

–**standing flexion test.** A screening test that determines the side of iliosacral somatic dysfunction (motion of ilium on the sacrum).

forward bending. Reciprocal of backward bending. *See also* flexion.

forward torsions. *See* sacrum, somatic dysfunctions of, forward torsions.

FRS. A descriptor of spinal somatic dysfunction used to denote a combination flexed (F), rotated (R), and sidebent (S) vertebral position.

–**FRS left.** A somatic dysfunction in which the vertebral unit is flexed, rotated, and sidebent left; usually preceded by a designation of the vertebral unit(s) involved (e.g., T5 FRS left or T5 FRLSL).

–**FRS right.** A somatic dysfunction in which the vertebral unit is flexed, rotated, and sidebent right; usually preceded by a designation of the vertebral unit(s) involved (e.g., C3-5 FRS right or C3-5 FRRSR).

frontal plane. See plane, coronal plane.

Fryette laws. See physiologic motion of the spine.

Fryette principles. See physiologic motion of the spine.

Fryette regional extension. See extension, regional extension.

Fryette regional flexion. See flexion, regional flexion.

FSR. A descriptor of spinal somatic dysfunction used to denote a combination flexed (F), sidebent (S), and rotated (R) vertebral position. See FRS.

functional treatment method. See osteopathic manipulative treatment, functional treatment.

functional technique. See osteopathic manipulative treatment, functional treatment method.

G

gait. A forward translation of the body's center of gravity by bipedal locomotion.

Galbreath treatment technique. See osteopathic manipulative treatment, mandibular drainage.

glymphatic system. A network of channels formed by glia in the central nervous system which functions as a waste clearance pathway for cerebrospinal fluid,

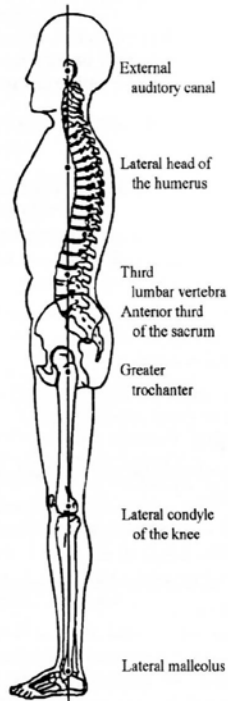


Figure 16. Gravitational line.

interstitial fluid, and interstitial solutes.

gravitational line. Viewing the patient from the side, an imaginary line in a coronal plane which, in the theoretical ideal posture, starts slightly anterior to the lateral malleolus, passes across the lateral condyle of the knee, the greater trochanter, through the lateral head of the humerus at the tip of the shoulder to the external auditory meatus; if this were a plane through the body, it would intersect the middle of the third lumbar vertebra and the anterior one third of the sacrum. It is used to evaluate the A-P (anterior-posterior) curves of the spine. *See also* mid-malleolar line. (Fig. 16)

H

habituation. Decreased physiologic response to repeated stimulation.

health. Adaptive and optimal attainment of physical, mental, emotional, spiritual, and environmental well-being.

hepatic pump. *See* osteopathic manipulative treatment, hepatic pump.

high velocity low amplitude treatment method (HVLA). *See* osteopathic manipulative

treatment, high velocity low amplitude.

hip bone. *See* innominate. *See also* innominate, somatic dysfunctions of.

homeostasis. (1) Maintenance of static or constant conditions in the internal environment. (2) The level of well-being of an individual maintained by internal physiologic harmony that is the result of a relatively stable state or equilibrium among the interdependent body functions.

homeostatic mechanism. A system of control activated by negative feedback.

Hoover technique. *See* osteopathic manipulative treatment, Hoover technique.

hysteresis. During the loading and unloading of connective tissue, the restoration of the final length of the tissue occurs at a rate and to an extent less than during deformation (loading). These differences represent energy loss in the connective tissue system. This difference in viscoelastic behavior (and energy loss) is known as hysteresis (or “stress-strain”).

hypertonicity. A condition of excessive resting tone of skeletal muscle characterized by increased resistance of the muscle to passive stretching.

HVLA. High velocity low amplitude. *See* osteopathic

manipulative treatment, high velocity low amplitude.

I

I/IND. Indirect method. *See* osteopathic manipulative treatment, indirect method.

ILA. Inferior lateral angle of the sacrum. *See* sacrum, inferior lateral angle of.

ilia. The plural of ilium. *See* ilium.

ilial compression test. *See* anterior superior iliac spine (ASIS) compression test.

ilial rocking test. *See* anterior superior iliac spine (ASIS) compression test.

iliosacral motion. Motion of one innominate (ilium) with respect to the sacrum. Iliosacral motion is part of pelvic motion during the gait cycle.

iliosacral dysfunction. *See* innominate somatic dysfunctions.

ilium. The expansive superior portion of the innominate (hip bone or os coxa). *See also* innominate.

indirect method. *See* osteopathic manipulative treatment, indirect method.

inferior ilium. *See* innominate, somatic dysfunctions of, inferior innominate shear.

inferior lateral angle of the sacrum (ILA). *See* sacrum, inferior lateral angle.

inferior pubis. *See* pubic bone, somatic dysfunctions of, inferior pubic shear.

inferior transverse axis. *See* sacral movement axis, inferior transverse axis.

inhalation rib. *See* rib somatic dysfunction, inhalation rib dysfunction.

inhalation rib restriction. *See* rib somatic dysfunction, exhalation rib dysfunction.

inhibition. *See* osteopathic manipulative treatment, inhibitory pressure.

inhibitory pressure technique. *See* osteopathic manipulative treatment, inhibitory pressure.

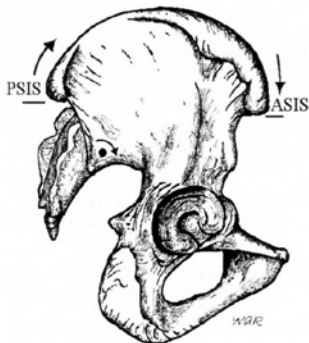
innominate. *Also called* the os coxa, hip bone, or pelvic bone. One of two large, irregularly shaped bones of the pelvis. Each consists of three parts: ilium, ischium, and pubis.

innominate rotation. Rotational motion of one innominate bone relative to the sacrum about the inferior transverse axis.

innominate somatic dysfunctions.

- anterior innominate rotation.** A somatic dysfunction in which the innominate bone is rotated anteriorly around a transverse axis relative to the sacrum. The innominate moves more

freely in anterior rotation and is restricted in posterior rotation. The anterior superior iliac spine (ASIS) is positioned inferiorly and the posterior superior iliac spine (PSIS) is positioned superiorly when compared to the contralateral landmarks.(Fig. 17)



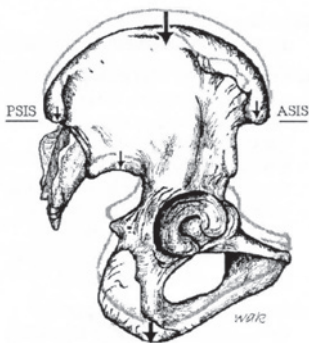
Standing flexion test = R(+)

Figure 17. Anterior right innominate rotation.

–downslipped innominate. See inferior innominate shear.

–inferior innominate shear. A somatic dysfunction in which the innominate bone translates inferiorly relative to the sacrum and becomes restricted. The innominate moves more freely in inferior translation and is restricted in superior translation. The anterior superior iliac spine (ASIS), posterior superior iliac spine (PSIS), and ischial tuberosity are positioned inferiorly when

compared to the contralateral landmarks. (Fig. 18)



Seated flexion test = R(+)

Figure 18. Right inferior innominate shear.

–inflared innominate. A somatic dysfunction in which the innominate bone becomes restricted such that the anterior superior iliac spine (ASIS) moves more freely in a medial direction and is restricted in the lateral direction. The anterior superior iliac spine (ASIS) is positioned medially and the posterior superior iliac spine (PSIS) is positioned laterally with respect to the midline when compared to the contralateral landmarks. (Fig. 19)

–outflared innominate. A somatic dysfunction in which the innominate bone becomes restricted such that the anterior superior iliac spine (ASIS) moves more

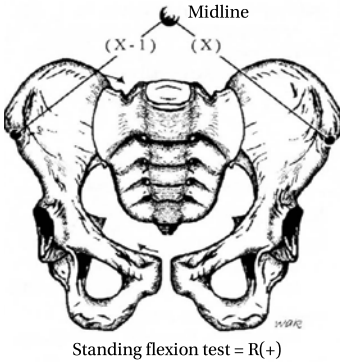


Figure 19. Inflared right innominate.

–posterior innominate rotation.
 A somatic dysfunction in which the innominate bone is rotated posteriorly around a transverse axis relative to the sacrum. The innominate moves more freely in posterior rotation and is restricted in anterior rotation. The anterior superior iliac spine (ASIS) is positioned superiorly and the posterior superior iliac spine (PSIS) is positioned inferiorly when compared to the contralateral landmarks. (Fig. 21)

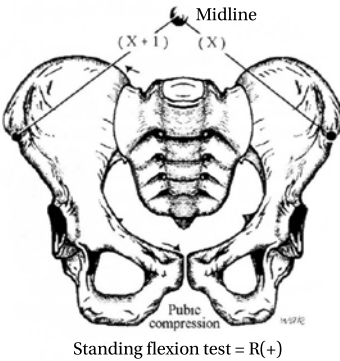


Figure 20. Outflared right innominate.

freely in a lateral direction and is restricted in the medial direction. The ASIS is positioned laterally and the posterior superior iliac spine (PSIS) is positioned medially with respect to the midline when compared to the contralateral landmarks. (Fig. 20)

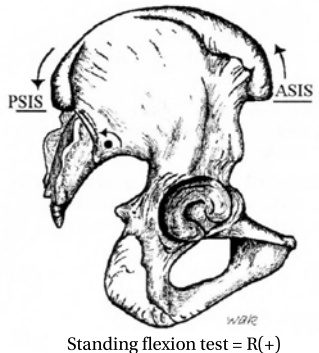
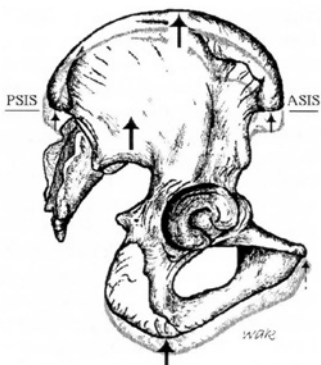


Figure 21. Right posterior innominate rotation.

–superior innominate shear.
 A somatic dysfunction in which the innominate bone translates superiorly relative to the sacrum and becomes restricted. The innominate moves more freely in superior translation and is restricted in inferior translation. The anterior superior iliac spine

(ASIS), posterior superior iliac spine (PSIS), and ischial tuberosity are positioned superiorly when compared to the contralateral landmarks. (Fig. 22)



Standing flexion test = R(+)

Figure 22. Right superior innominate shear.

–upslipped innominate. See superior innominate shear.

integrated neuromusculoskeletal release. See osteopathic manipulative treatment, integrated neuromusculoskeletal release.

intersegmental motion. Designates relative motion taking place between two adjacent vertebral segments or within a vertebral unit that is described as the upper vertebral segment moving on the lower.

intrinsic corrective forces. Voluntary or involuntary forces from within the patient that assist in the manipulative treatment process. See also extrinsic corrective forces.

isokinetic exercise. Exercise using a constant speed of movement of the body part.

isolytic contraction. See contraction, isolytic.

isometric contraction. See contraction, isometric.

isotonic contraction. See contraction, isotonic.

J

Jones technique. See osteopathic manipulative treatment, counterstrain.

junctional region. See transitional region.

K

key lesion. See somatic dysfunction, primary.

kinesthesia. The sense by which muscular motion, weight, position, etc. are perceived.

kinesthetic. Pertaining to kinesthesia.

kinetics. The body of knowledge that deals with the effects of

forces that produce or modify body motion.

klapping. Striking the skin with cupped palms to produce vibrations with the intention of loosening material in the lumen of hollow tubes or sacs within the body, particularly the lungs.

kneading. A soft tissue technique that utilizes an intermittent force applied perpendicular to the long axis of the muscle.

kyphoscoliosis. A spinal curve pattern combining kyphosis and scoliosis. *See also* kyphosis; scoliosis.

kyphosis. (1) The exaggerated (pathologic) or normal A-P (anteroposterior) curve of the thoracic spine with concavity anteriorly. (2) Abnormally increased convexity in the curvature of the thoracic spine in the lateral view.

kyphotic. Pertaining to or characterized by kyphosis. *See also* kyphosis.

L

lateral flexed vertebral body. *See* sidebent.

lateral flexion. *Also called* lateroflexion. *See* sidebending.

lateral masses (of the atlas). The bulkiest and solid parts of the atlas that support the weight of the head.

lateroflexion. *See* sidebending.

law.

–**Fryette law of motion.** *See* physiologic motion of the spine.

–**Head Law.** When a painful stimulus is applied to a body part of low sensitivity (e.g., viscus) that is in close central connection with a point of higher sensitivity (e.g., soma), the pain is felt at the point of higher sensitivity rather than at the point where the stimulus was applied.

–**Sherrington Law.** (1) Every posterior spinal nerve root supplies a specific region of the skin, although fibers from adjacent spinal segments may invade such a region. (2) When a muscle receives a nerve impulse to contract, its antagonist receives, simultaneously, an impulse to relax. These are only two of Sherrington's contributions to neurophysiology; these are the ones most relevant to osteopathic principles.

–**Wolff Law.** Every change in form and function of a bone, or in its function alone, is followed by certain definite changes in its internal architecture, and secondary alterations in its external conformations (e.g., bone is laid down along lines of stress). (*Stedman's*)

lesion (osteopathic)

lesion (osteopathic). Historic term used to describe somatic dysfunction. *See* somatic dysfunction.

ligamentous.

–**ligamentous articular strain (LAS).** Any somatic dysfunction resulting in abnormal ligamentous tension or strain. *See also* osteopathic manipulative treatment, ligamentous articular strain technique.

–**ligamentous articular strain technique (LAS).** *See* osteopathic manipulative treatment, ligamentous articular strain technique.

–**strain ligamentous.** Motion and/or positional asymmetry associated with elastic deformation of connective tissue (fascia, ligament, membrane). *See* strain; ligamentous articular strain.

line of gravity. *See* gravitational line.

linkage. A somatic dysfunctional segmental behavior where a single vertebra and an adjacent rib respond to the same regional motion tests with identical asymmetric behaviors (rather than opposing behaviors). This suggests visceral reflex inputs.

liver pump. *See* osteopathic manipulative treatment, hepatic pump technique.

load. The application of a biomechanical force

(compression, distraction, or torsion) by the osteopathic practitioner directed to a specific anatomic structure or tissue.

localization. (1) In manipulative technique, the precise positioning of the patient and vector application of forces required to produce a desired result. (2) The reference of a sensation to a particular locality in the body.

longitudinal axis. *See* sacral motion axis, longitudinal axis.

lordosis. The anterior convexity in the curvature of the lumbar and cervical spine as viewed from the lateral view. The term is used to refer to both an abnormally increased curvature (also called hollow back, saddle back, sway back) and to the normal curvature (normal lordosis).

lordotic. Pertaining to or characterized by lordosis.

lumbarization. *See* transitional vertebrae, lumbarization.

lumbolumbar lordotic angle. *See* angle, lumbolumbar lordotic.

lumbosacral angle. *See* angle, lumbosacral.

lumbosacral lordotic angle. *See* angle, lumbosacral lordotic.

lumbosacral spring test. *See* spring test.

lymphatic pumps. *See* osteopathic manipulative treatment, lymphatic pump. *See also*

osteopathic manipulative treatment, pedal pump. *See also* osteopathic manipulative treatment, thoracic pump technique.

lymphatic treatment. *See* osteopathic manipulative treatment, lymphatic technique.

M

mandibular drainage technique. *See* osteopathic manipulative treatment, mandibular drainage technique.

manipulation. Therapeutic application of manual force. *See also* technique; osteopathic manipulative treatment.

manual medicine. (1) The skillful use of the hands to diagnose and treat structural and functional abnormalities in various tissues and organs throughout the body, including bones, joints, muscles, and other soft tissues as an integral part of complete medical care. (2) This term originated from the German *Manuelle Medizin* (manual medicine) and has been used interchangeably with the term manipulation. (3) This term is not identical to manual therapy, which has been used by non-physician practitioners (e.g., physical therapists).

massage. Therapeutic friction, stroking, and kneading of the

body. *See also* osteopathic manipulative treatment, soft tissue treatment method.

membranous articular strain. Any cranial somatic dysfunction resulting in abnormal dural membrane tensions.

membranous balance. The ideal physiologic state of harmonious equilibrium in the tension of the dura mater of the brain and spinal cord.

mesenteric lift. *See* osteopathic manipulative treatment, mesenteric release technique.

mesenteric release technique. *See* osteopathic manipulative treatment, mesenteric release technique.

middle transverse axis. *See* sacral motion axis, middle transverse axis (postural).

mid-heel line. A vertical line used as a reference in standing antero-posterior (A-P) x-rays and postural evaluation, passing equidistant between the heels.

mid-gravitational line. *See* gravitational line.

mid-malleolar line. A vertical line passing through the lateral malleolus, used as a point of reference in standing lateral x-rays and postural evaluation. *See also* gravitational line.

mirror-image motion asymmetries. A grouping of primary and secondary sites of somatic

dysfunction describing a three-segment complex fundamental to dysfunction in a mobile system. Each adjacent segment, above and below the primary locus, demonstrates opposing asymmetries to that locus. For example, if the primary locus resists rotation right, the segments above and below resist rotation left.

mobile point. In counterstrain, the final position of treatment at which tenderness is no longer elicited by palpation of the tender point. *See also* counterstrain.

mobile segment. A term in functional methods to describe a bony structure with its articular surfaces and adnexal tissues (neuromuscular and connective) for segmental motion which affects movement, stabilizes position, and allows coordinated participation in passive movement.

mobile system. An osteopathic construct associated with functional methods in which the body as a whole is viewed as a centrally integrated system in which all of the individual elements (e.g., mobile segments) have coordinated and specific motion characteristics. *See also* osteopathic manipulative treatment, functional method.

mobile unit. *See* mobile segment.

models of osteopathic care.

Five models that articulate how an osteopathic practitioner

seeks to influence a patient's physiological processes.

–**behavioral model.** The goal of this model is to improve the biological, psychological, and social components of the health spectrum. This includes emotional balancing and compensatory mechanisms. Reproductive processes and behavioral adaptation are also included under this model.

–**metabolic model.** The goal of the metabolic model is to enhance the self-regulatory and self-healing mechanisms, to foster energy conservation by balancing the body's energy expenditure and exchange, and to enhance immune system function, endocrine function, and organ function. The osteopathic considerations in this area are not manipulative in nature except for the use of lymphatic pump techniques. Nutritional counseling, diet, and exercise advice are the most common approaches to balancing the body through this model.

–**neurologic model.** The goal of the neurologic model is to attain autonomic balance and address neural reflex activity, remove facilitated segments, decrease afferent nerve signals and relieve pain. The osteopathic manipulative techniques used to influence this area of patient health

include counterstrain and Chapman reflex points.

–**respiratory-circulatory model.**

The goal of the respiratory-circulatory model is to improve all of the diaphragm restrictions in the body.

Diaphragms are considered to be “transverse restrictors” of motion, venous and lymphatic drainage, and cerebrospinal fluid. The techniques used in this model are osteopathic cranial manipulative medicine, ligamentous articular strain, myofascial release, and lymphatic pump techniques.

–**structural model.** The goal of the structural model is biomechanical adjustment and the mobilization of joints. This model also seeks to address problems in the myofascial connective tissues, as well as in the bony and soft tissues, to remove restrictive forces and enhance motion. This is accomplished by the use of a wide range of osteopathic manipulative techniques such as high velocity low amplitude, muscle energy, counterstrain, myofascial release, ligamentous articular techniques, and functional techniques.

motion. (1) A change of position (rotation and/or translation) with respect to a fixed system. (2) An act or process of a body changing position in terms of direction, course, and velocity.

–**active motion.** Movement produced voluntarily by the patient.

–**inherent motion.** Spontaneous motion of every cell, organ, system, and their component units within the body.

–**passive motion.** Motion induced by the osteopathic practitioner while the patient remains passive or relaxed.

–**physiologic motion.** Changes in position of body structures within the normal range. *See also* physiologic motion of the spine.

MFR. *See* osteopathic manipulative treatment, myofascial release.

muscle energy technique. *See* osteopathic manipulative treatment, muscle energy.

myofascial release technique. *See* osteopathic manipulative treatment, myofascial release.

myofascial technique. *See* osteopathic manipulative treatment, myofascial release, myofascial technique.

myofascial trigger point. *See* trigger point, myofascial.

myogenic tonus. (1) Tonic contraction of muscle dependent on some property of the muscle itself or of its intrinsic nerve cells. (2) Contraction of a muscle caused by intrinsic properties of the muscle or by its intrinsic innervation (*Stedman's*).

myotome. (1) All muscles derived from one somite and innervated by one segmental spinal nerve. (*Stedman's*) (2) That part of the somite that develops into skeletal muscle.

N

Neuromusculoskeletal Medicine (NMM). The specialty within osteopathic medicine that emphasizes the incorporation of osteopathic manual diagnosis and osteopathic manipulative treatment into the evaluation and treatment of the nervous, muscular, and skeletal systems in their relationships to other systems of the body as well as the whole person. *See also* Certification in Neuromusculoskeletal Medicine. *See also* Osteopathic Neuromusculoskeletal Medicine (ONMM).

neurotrophicity. *See* neurotrophy.

neurotrophy. The nutrition and maintenance of tissues as regulated by direct innervation.

neutral. (1) The range of sagittal plane spinal positioning in which the first principle of physiologic motion of the spine applies. (2) A point of tissue or articular balance from which all motions physiologic to that structure may take place. *See also* physiologic motion of the spine. (Fig. 23)

NMM. *See* Neuromusculoskeletal Medicine. *See also* Osteopathic Neuromusculoskeletal Medicine.

NMM-OMM.

Neuromusculoskeletal Medicine-Osteopathic Manipulative Medicine. *See* Osteopathic Neuromusculoskeletal Medicine.

non-neutral. The range of sagittal plane spinal positioning in which the second principle of physiologic motion of the spine applies. *See also* extension. *See also* flexion. *See also* physiologic motion of the spine.

non-allopathic lesion. Historic term used to describe somatic dysfunction. *See* somatic dysfunction.

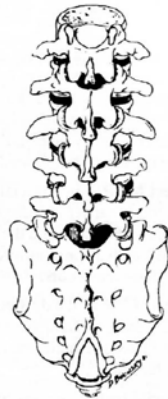

Figure 23. Neutral spinal position.

normalization. The therapeutic use of anatomic and physiologic mechanisms to facilitate the body's response toward homeostasis and improved health.

NSR. A descriptor of spinal somatic dysfunction used to denote a combination neutral (N), sidebent (S), and rotated (R) vertebral position; similar descriptors may involve flexed (F) and extended (E) position.

nutiation. Nodding forward; anterior movement of the sacral base around a transverse axis in relation to the ilia.

O

oblique axis. *See* sacral motion axis, oblique axis (diagonal).

OCMM. *See* osteopathic manipulative treatment, osteopathic cranial manipulative medicine.

OMM. *See* osteopathic manipulative medicine.

OMT. *See* osteopathic manipulative treatment.

OMTh. *See* osteopathic manipulative therapy.

ONMM. *See* Osteopathic Neuromusculoskeletal Medicine.

OP&P. Historic term for osteopathic principles and practice. *See also* osteopathic philosophy.

OPP. Osteopathic principles and practice. *See also* osteopathic philosophy.

os coxa. *See* innominate.

osteopath. (1) A person who has achieved the nationally recognized academic and professional standards within her or his country to independently practice diagnosis and treatment based upon the principles of osteopathic philosophy. Individual countries establish the national academic and professional standards for osteopaths practicing within their countries (international usage). (2) Considered by the American Osteopathic Association (AOA) to be an historic term when applied to graduates of U.S. schools. *See also* DO.

osteopathic lesion (complex). *Also called* non-allopathic lesion. Historic term used to describe somatic dysfunction. *See* somatic dysfunction.

osteopathic manipulative medicine (OMM). The application of osteopathic philosophy, structural diagnosis and use of osteopathic manipulative treatment (OMT) in the diagnosis and management of the patient. *See also* osteopathic manipulative treatment (OMT).

osteopathic manipulative therapy (OMTh). The therapeutic application of manually guided forces by an osteopath

(non-physician) to improve physiological function and homeostasis that has been altered by somatic dysfunction.

osteopathic manipulative treatment (OMT). The therapeutic application of manually guided forces by an osteopathic physician (U.S. usage) to improve physiologic function and/or support homeostasis that has been altered by somatic dysfunction.

–**active method.** Any technique in which the patient voluntarily performs an osteopathic practitioner-directed motion.

–**articular treatment.** Historic term. *See* osteopathic manipulative treatment, articular.

–**articular.** A direct treatment method employing a low velocity/moderate to high amplitude force applied to a dysfunctional joint. The osteopathic practitioner can choose to employ a repetitive springing motion or a single movement of the joint through the restrictive barrier.

–**balanced ligamentous tension (BLT).** A treatment method that is a regional interpretation based on the article “Osteopathic Technique of William G. Sutherland,” published in the 1949 Year Book of Academy of Applied Osteopathy. The method involves the minimization of peri-articular tissue load and

the placement of the affected ligaments in a position of equal tension in all appropriate planes so that the body’s inherent forces can resolve the somatic dysfunction. *See also* ligamentous articular strain. *See also* balanced ligamentous tension (BLT).

–**balanced membranous tension (BMT).** Any OCMM method in which the goal of treatment is to achieve a state in which the affected craniosacral structures are equalized in all appropriate planes. *See also* balanced membranous tension (BMT). *See also* osteopathic cranial manipulative medicine (OCMM).

–**Chapman reflex treatment.** A treatment method in which either classic rotatory motion or other methods used to address soft tissue dysfunction are applied to Chapman reflex points. *See* Chapman reflex.

–**combined treatment method.** (1) A treatment strategy where the initial movements are indirect; as the technique is completed the movements change to direct forces. (2) A manipulative sequence involving two or more different osteopathic manipulative treatment method (e.g., Spencer technique combined with muscle energy technique). (3) A concept described by Paul Kimberly, DO.

–**combined treatment.** Historic term. *See* osteopathic manipulative treatment, combined treatment method.

–**compression of the fourth ventricle (CV-4).** A cranial technique in which the lateral angles of the occipital squama are manually approximated slightly exaggerating the posterior convexity of the occiput and taking the cranium into sustained extension. *See also* osteopathic cranial manipulative medicine (OCMM).

–**counterstrain (CS).** (1) An osteopathic method of diagnosis and indirect treatment in which the patient’s somatic dysfunction, diagnosed by an associated myofascial tender point, is treated by using a position of spontaneous tissue release while simultaneously monitoring the tender point. (2) Developed by Lawrence Jones, DO, FAAO, in 1955 (originally “spontaneous release by positioning”; it was later termed “strain-counterstrain”).

–**cranial treatment (CR).** *See* osteopathic cranial manipulative medicine (OCMM). *See also* primary respiratory mechanism.

–**CV-4.** *See* compression of the fourth ventricle. *See also* osteopathic cranial

manipulative medicine (OCMM).

–**Dalrymple technique.** *See also* osteopathic manipulative treatment, pedal pump.

–**direct method (technique).** An osteopathic treatment in which the restrictive barrier is engaged and a final activating force is applied to correct somatic dysfunction.

–**exaggeration.** An osteopathic treatment method in which the body part is moved slightly farther toward the direction of dysfunction so that the body’s inherent forces can correct the somatic dysfunction.

–**exaggeration technique.** An indirect procedure that involves carrying the dysfunctional part away from the restrictive barrier, then applying a high velocity low amplitude force in the same direction.

–**facilitated oscillatory release (FOR).** (1) A treatment method intended to normalize neuromuscular function by applying a manual oscillatory force, which may be combined with any other ligamentous or myofascial technique. (2) A refinement of a long-standing use of oscillatory force in osteopathic diagnosis and treatment as published in early osteopathic literature. (3) A technique developed by Zachary Comeaux, DO as an extension of his work with Robert Fulford, DO.

–facilitated positional release (FPR). (1) A treatment method in which a dysfunctional body region is addressed with a combination of neutral positioning, application of an activating force (compression, torsion, or distraction), and placement into position of ease. (2) A technique developed by Stanley Schiowitz, DO.

–fascial release treatment. See osteopathic manipulative treatment, myofascial release.

–fascial unwinding. A treatment method in which the osteopathic practitioner moves the dysfunctional fascial tissues in response to a sensation of ease and bind in a dynamic continuous process.

–functional method. An indirect treatment utilizing passive regional motion input in multiple directions to encourage optimal ease of the somatic dysfunction. The osteopathic practitioner guides the manipulative procedure while the dysfunctional area is being monitored in order to obtain a continuous feedback of the neurophysiologic response to increased ease of motion.

–Galbreath technique. See osteopathic manipulative treatment, mandibular drainage.

–hepatic pump technique. Rhythmic compression applied over the liver for purposes of increasing blood flow through

the liver and enhancing bile and lymphatic drainage from the liver.

–high velocity low amplitude (HVLA). Also called thrust treatment method. An osteopathic method in which the restrictive barrier is engaged in one or more planes of motion and then a rapid, therapeutic force of brief duration traveling a short distance is applied within the anatomic range of motion.

–Hoover technique. (1) A form of functional method. (2) Developed by H.V. Hoover, DO. See also osteopathic manipulative treatment, functional method.

–indirect method (I/IND). A manipulative treatment in which the restrictive barrier is disengaged and the dysfunctional body part is moved away from the restrictive barrier.

–inhibitory pressure. A treatment method in which steady pressure is applied to soft tissues to reduce reflex activity and promote tissue relaxation.

–integrated neuromusculoskeletal release (INR). A treatment method in which indirect, direct, and/or release enhancing maneuvers are applied to reflexively influence the biomechanics of the musculoskeletal system

and respective peripheral and central neural control mechanisms.

–**Jones technique.** *See* osteopathic manipulative treatment, counterstrain.

–**ligamentous articular strain (LAS).** (1) A treatment method based on a geographical interpretation of the article “Osteopathic Technique of William G. Sutherland,” published in the *1949 Year Book of Academy of Applied Osteopathy*. The method involves disengagement, exaggeration and taking the dysfunctional opposing ligaments to a point of balance. (2) A set of myofascial release techniques described by Howard Lippincott, DO, and Rebecca Lippincott, DO. (3) Title of reference work by Conrad Speece, DO, and William Thomas Crow, DO. *See also* balanced ligamentous tension.

–**liver pump.** *See* osteopathic manipulative treatment, hepatic pump technique.

–**lymphatic technique.** A diverse group of techniques designed to remove impediments to lymphatic circulation and promote and augment the flow of interstitial fluid and lymph.

–**lymphatic pump.** (1) A term used to describe the impact of intrathoracic pressure changes on lymphatic flow. This was

the name originally given to the thoracic pump technique before the more extensive physiologic effects of the technique were recognized. (2) A term coined by C. Earl Miller, DO. *See* osteopathic manipulative treatment, thoracic pump technique.

–**mandibular drainage technique.** Soft tissue manipulative technique using passively induced jaw motion to improve drainage of middle ear structures via the eustachian tube and lymphatics. A technique first described by William Otis Galbreath, DO.

–**mesenteric release technique (mesenteric lift).** A technique in which the double layer of peritoneum that invests the intestines and its associated vascular, neural and lymphatic structures is relieved of tension from the attachments to the posterior wall of the abdomen which include the root of the mesentery, hepatic and splenic flexures and ascending and descending colon.

–**muscle energy.** (1) A direct treatment method which the patient’s muscles are employed upon request, from a precisely controlled position, in a specific direction, and against a distinctly executed physician counterforce. (2) First described in 1948 by Fred Mitchell, Sr, DO.

–**myofascial release (MFR).**

A treatment method first described by Andrew Taylor Still, MD, DO, and his early students, which utilizes continual palpatory feedback to alleviate restriction of the somatic dysfunction and its related fascia and musculature. *See also* direct myofascial release; indirect myofascial release.

–**direct myofascial release.**

The dysfunctional myofascial tissues are loaded and restrictive barrier is engaged with a constant force.

–**indirect myofascial release.**

The dysfunctional myofascial tissues are loaded and then guided towards the position of greatest ease.

–**myofascial technique.** Any technique directed at the muscles and fascia. *See also* osteopathic manipulative treatment, myofascial release. *See also* osteopathic manipulative treatment, soft tissue method.

–**osteopathy in the cranial field (OCF).** Historic term. (1) Refers to the system of diagnosis and treatment first described by William G. Sutherland, DO. (2) Title of reference work by Harold Magoun, Sr, DO. *See* Osteopathic Cranial Manipulative Medicine.

–**osteopathic cranial manipulative medicine (OCMM).**

A system of diagnosis and treatment by an osteopathic

practitioner using the primary respiratory mechanism and balanced membranous tension. *See also* primary respiratory mechanism. *See also* balanced membranous tension. *See also* osteopathy in the cranial field (OCF).

–**passive method.** Any technique in which the patient is instructed to refrain from voluntary muscle contraction.

–**pedal pump.** *Also called* the pedal fascial pump; Dalrymple treatment. A venous and lymphatic drainage technique applied through the lower extremities.

–**percussion vibrator method.** (1)

A treatment method involving the specific application of mechanical vibratory force to treat somatic dysfunction. (2)

An osteopathic manipulative technique developed by Robert Fulford, DO.

–**progressive inhibition of neuromuscular structures (PINS).** (1)

A method of diagnosis and treatment in which the osteopathic practitioner localizes sensitive points and sequentially applies inhibitory pressure along a predictable pathway to this series of related points. (2)

Developed by Dennis Dowling, DO.

–**soft tissue method (ST).** A group of direct techniques that usually involve lateral stretching, linear stretching,

deep pressure, traction and/or separation of muscle origin and insertion while monitoring tissue response and motion changes by palpation. Historically considered a form of myofascial treatment.

–**Spencer technique.** A series of direct manipulative procedures to prevent or decrease soft tissue and articular motion restrictions about the shoulder. *See also* osteopathic manipulative treatment, articular treatment (ART).

–**splenic pump technique.** Rhythmic compression applied over the spleen for the purpose of enhancing the patient's immune response. *See also* osteopathic manipulative treatment, lymphatic pump.

–**spontaneous release by positioning.** *See* osteopathic manipulative treatment, counterstrain.

–**springing.** A low velocity/moderate to high amplitude activating force using pressure and motion applied repeatedly against the restrictive barrier of a dysfunctional structure. *See also* osteopathic manipulative treatment, articular

–**strain counterstrain.** *See* osteopathic manipulative treatment, counterstrain.

–**Still technique.** (1) A combined manipulative method utilizing both indirect and direct components. The

dysfunctional region is first placed in an indirect position, an axial force (compression, traction, torsion) is added and then used to carry the region directly past neutral toward or through its restrictive barrier. (2) Attributed to Andrew Taylor Still, MD, DO. (3) Title of reference work by Richard Van Buskirk, DO, PhD, FAAO.

–**thoracic pump technique.** (1) A technique that consists of intermittent compression of the thoracic cage. (2) Developed by C. Earl Miller, DO.

–**thrust technique.** *See* osteopathic manipulative treatment, high velocity low amplitude technique (HVLA).

–**traction technique.** A procedure in which the parts are stretched or separated along a longitudinal axis with continuous or intermittent force.

–**v-spread.** Technique using forces transmitted across the diameter of the cranium to improve sutural motion.

–**ventral technique.** *See* osteopathic manipulative treatment, visceral manipulation.

–**visceral manipulation (VIS).** Historically called ventral techniques. A method of diagnosis and treatment directed to the viscera and/or the supportive structures to improve physiologic function.

osteopathic manipulative treatment method. A group of techniques that apply to a set of distinct unifying principles that guide individualized treatment.

osteopathic manipulative treatment technique. A specific therapeutic manual procedure, e.g. Dalrymple pedal pump, Galbreath mandibular drainage, pectoral traction, CV-4.

osteopathic medicine. The preferred term for a complete system of medical care practiced by physicians with an unlimited license that is represented by a philosophy that combines the needs of the patient with the current practice of medicine, surgery and obstetrics. Emphasizes the interrelationship between structure and function, and has an appreciation of the body's ability to heal itself.

osteopathic musculoskeletal evaluation. The osteopathic musculoskeletal evaluation provides information regarding the health of the patient. Utilizing the concepts of body unity, self-regulation and structure-function interrelationships, the osteopathic physician uses data from the musculoskeletal evaluation to assess the patient's status and develop a treatment plan. (*AOA House of Delegates.*)

Osteopathic Neuromusculoskeletal Medicine (ONMM). The osteopathic neuromusculoskeletal medicine residency program is

a primary residency disciplined in the neuromusculoskeletal system, its comprehensive relationship to other organ systems, and its dynamic function of locomotion. The principle focus of the discipline is osteopathic and patient-centered; specifically, it embodies structural and functional interrelation, body unity, self-healing, and self-maintenance. *See also* Certification in Neuromusculoskeletal Medicine and Osteopathic Manipulative Medicine (C-NMM/OMM). *See also* Neuromusculoskeletal Medicine (NMM).

osteopathic philosophy. A concept of health care supported by expanding scientific knowledge that embraces the concept of the unity of the living organism's structure (anatomy) and function (physiology). Emphasizes the following principles. (1) The human being is a dynamic unit of function; (2) The body possesses self-regulatory mechanisms that are self-healing in nature; (3) Structure and function are interrelated at all levels; (4) Rational treatment is based on these principles.

osteopathic physician. A person with full unlimited medical practice rights who has achieved the nationally recognized academic and professional standards within his or her country to practice diagnosis and treatment based upon

the principles of osteopathic philosophy. Individual countries establish the national academic and professional standards for osteopathic physicians practicing within their countries.

osteopathic postural examination.

The part of the osteopathic structural examination that focuses on the static and dynamic responses of the body to gravity while in the erect position.

osteopathic practitioner. Refers to an osteopath, an osteopathic physician or an allopathic physician who has been trained in osteopathic principles, practices and philosophy.

osteopathic principles. *See* osteopathic philosophy.

osteopathic principles and practices (OPP). *See* osteopathic philosophy

osteopathic structural examination. The examination of a patient by an osteopathic practitioner with emphasis on the neuromusculoskeletal system as it reflects and interacts with other body systems in the context of total patient care. This is accomplished primarily via inspection, motion testing, and palpation with the goal of determining the cause of the patient's complaint and any somatic dysfunction that may be associated with it. Using the concepts of body unity, self-regulation and structure-function interrelationships; the findings

of the structural examination, osteopathic practitioner guide the osteopathic practitioner to the appropriate choice of treatment.

osteopathic tenets.

See osteopathic philosophy.

osteopathy. Historic term. No longer a preferred term in the United States. *See* osteopathic medicine.

P

palpation. The application of the fingers to the surface of the skin or other tissues, using varying amounts of pressure, to selectively determine the condition of the parts beneath.

palpatory diagnosis. A term used by osteopathic practitioners to denote the process of palpating the patient to evaluate the structure and function of the neuromusculoskeletal and visceral systems.

palpatory skills. Sensory skills used in performing palpatory diagnosis and osteopathic manipulative treatment.

passive method. *See* osteopathic manipulative treatment, passive method.

passive motion. *See* motion, passive motion.

patient cooperation. Voluntary movement by the patient (on instruction from the osteopathic

pedal pump

practitioner) to assist in the palpatory diagnosis and treatment process.

pedal pump. See osteopathic manipulative treatment, pedal pump.

pelvic bone. See innominate.

pelvic declination (pelvic unleveling). Pelvic rotation about an anterior-posterior (A-P) axis.

pelvic girdle dysfunction. See somatic dysfunction, pelvic.

pelvic index (PI). Represents a ratio of the measurements determined from postural radiograph. One (y) beginning from a vertical line originating at the sacral promontory to the intersection with the horizontal line from the anterior-superior position of the pubic bone. The second measurement (x) is along this same horizontal line. Normal values are age-related and increase in subjects with sagittal plane postural decompensation. Pelvic index (PI) equals x/y . (Fig. 24)

pelvic rotation. Movement of the entire pelvis in a relatively horizontal plane about a vertical (longitudinal) axis.

pelvic sideshift. Deviation of the pelvis to the right or left of the central vertical axis as translation occurs along the horizontal (z) axis. Usually observed in the standing position.

pelvic somatic dysfunctions. A group of somatic dysfunctions

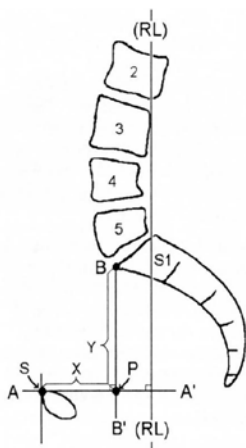


Figure 24. Pelvic index (PI).
(Modified from Kuchera WA, Kuchera ML, *Osteopathic Principles in Practice*, Greyden Press, Columbus, OH, 1994:263).

involving the sacrum and innominate. See somatic dysfunction. See somatic dysfunction, innominate.

pelvic tilt. Pelvic rotation about a transverse (horizontal) axis (forward or backward tilt) or about an anterior-posterior axis (right or left side tilt).

pelvis. Within the context of structural diagnosis, the pelvis is made up of the right and left innominates, (hip bones or os coxae) the sacrum and coccyx.

percussion vibrator technique. See osteopathic manipulative treatment, percussion vibrator technique.

pétrissage. Deep kneading or squeezing action to express swelling.

physiologic barrier. *See* barrier, physiologic barrier.

physiologic motion. *See* motion, physiologic motion.

physiologic motion of the spine. The three major principles of physiologic motion are:

I. When the thoracic and lumbar spine are in a neutral position (easy normal), the coupled motions of sidebending and rotation for

a group of vertebrae are such that sidebending and rotation occur in opposite directions (with rotation occurring toward the convexity). (Fig. 25) *See* somatic dysfunction, type I somatic dysfunction.

II. When the thoracic and lumbar spine are sufficiently forward or backward bent (non-neutral), the coupled motions of sidebending and rotation in a single vertebral unit occur in the same direction. (Fig. 26) *See* somatic dysfunction, type II, somatic dysfunction.

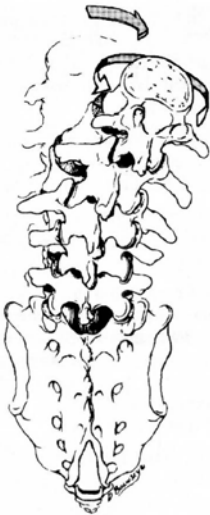

Figure 25. Physiologic motion of the thoracic or lumbar spine resulting from a neutral spinal position (Type I motion).

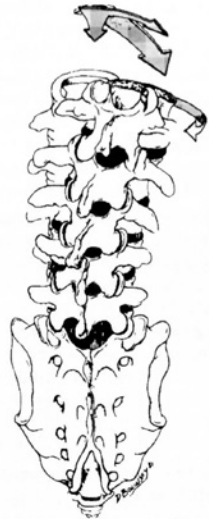

Figure 26. Physiologic motion of the thoracic or lumbar spine resulting from a non-neutral spinal position (Type II motion).

III. Initiating motion of a vertebral segment in any plane of motion will modify the movement of that segment in other planes of motion.

Principles I and II of thoracic and lumbar spinal motion were described by Harrison H. Fryette, DO (1918); Principle III was described by C.R. Nelson, DO (1948). *See* rotation. *See also* rotation of vertebra.

PINS. *See* progressive inhibition of neuromuscular structures (PINS).

plane. A flat surface determined by the position of three points in space. Any of a number of imaginary surfaces passing through the body and dividing it into segments. (Fig. 27)

–**AP plane.** *See* plane, sagittal plane.

–**coronal plane (frontal plane).** A plane passing longitudinally through the body from one side to the other, and dividing the body into anterior and posterior portions.

–**frontal plane.** *See* plane, coronal plane.

–**horizontal plane.** *See* plane, transverse plane.

–**sagittal plane.** A plane passing longitudinally through the body from front to back and dividing it into right and left portions. The median or midsagittal plane divides the body into approximately equal right and left portions.

–**transverse plane (horizontal plane).** A plane passing horizontally through the body perpendicular to the sagittal and frontal planes, dividing the body into upper and lower portions.

plastic deformation. A non-recoverable deformation. *See also* elastic deformation.

plasticity. Ability to retain a shape attained by deformation. *See also* elasticity. *See also* viscosity.

posterior component. A positional descriptor used to identify the side of reference when rotation of a vertebral segment has occurred. In a condition of right rotation, the right side is the posterior component. It usually refers to a prominent vertebral transverse process. *See also* anterior component.

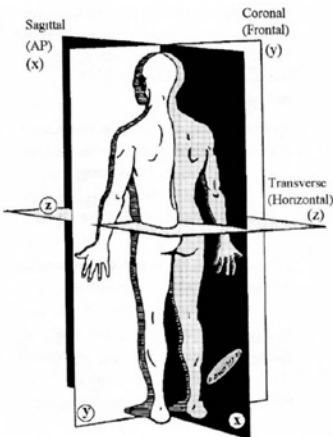


Figure 27. Planes of the body.

posterior nutation. *See* counternutation.

post-isometric relaxation. Immediately following an isometric contraction, the neuromuscular apparatus is in a refractory state during which enhanced passive stretching may be performed. The osteopathic practitioner may take up the myofascial slack during the relaxed refractory period.

postural axis. *See* sacral motion axis, postural axis.

postural balance. A condition of optimal distribution of body mass in relation to gravity.

postural decompensation. Distribution of body mass away from ideal when postural homeostatic mechanisms are overwhelmed. It occurs in all cardinal planes, but is classified by the major plane(s) affected. *See* plane. (Fig. 27)

–**coronal plane postural decompensation.** Causes scoliotic changes.

–**horizontal plane postural decompensation.** May cause postural changes where part or all of the body rotates to the right or left. When viewed from the right or left sides, alignment appears asymmetrical.

–**sagittal plane postural decompensation.** Causes kyphotic and/ or lordotic changes.

postural imbalance. A condition in which ideal body mass distribution is not achieved.

primary machinery of life. (1) The neuromusculoskeletal system. A term used to denote that body parts act together to transmit and modify force and motion through which person acts out his or her life. This integration is achieved via the central nervous system acting in response to continued sensory input from the internal and external environment. (2) A term coined by I.M. Korr, PhD.

primary respiratory mechanism.

(1) A conceptual model that describes a process involving five interactives, involuntary functions.

1. The inherent motility of the brain and spinal cord.
2. Fluctuation of the cerebrospinal fluid.
3. Mobility of the intracranial and intraspinal membranes.
4. Articular mobility of the cranial bones.
5. Mobility of the sacrum between the ilia (pelvic bones) that is interdependent with the motion at the sphenobasilar synchondrosis.

The mechanism refers to the presumed inherent (primordial) driving mechanism of internal respiration as opposed to the cycle of diaphragmatic respiration (inhalation and exhalation). It further refers to the

innate interconnected movement of every tissue and structure of the body. Optimal health promotes optimal function and the inherent function of this interdependent movement can be negatively altered by trauma, disease states or other pathology.

(2) This mechanism was first described by William G. Sutherland, DO, in 1939 in his self-published volume, "The Cranial Bowl." The mechanism is thought to affect cellular respiration and other body processes. In the original definition, the following descriptions were given:

–**primary.** Because it is directly concerned with the internal tissue respiration of the central nervous system.

–**respiratory.** Because it further concerns the physiological function of the interchange of fluids necessary for normal metabolism and biochemistry, not only of the central nervous system, but also of all body cells.

–**mechanism.** Because all the constituent parts work together as a unit carrying out this fundamental physiology. *See also* osteopathic manipulative treatment; osteopathic cranial manipulative medicine (OCMM).

prime mover. A muscle primarily responsible for causing a specific joint action.

progressive inhibition of neuromuscular structures (PINS).

See osteopathic manipulative treatment, progressive inhibition of neuromuscular structures.

prolotherapy. *See* sclerotherapy.

pronation. In relation to the anatomical position, as applied to the hand, rotation of the forearm in such a way that the palmar surface turns backward (internal rotation) in relationship to the anatomical position. Applied to the foot, a combination of eversion and abduction movements taking place in the tarsal and metatarsal joints, resulting in lowering of the medial margin of the foot. *See also* supination.

prone. Lying face downward (*Stedman's*).

psoas syndrome. A painful low back condition characterized by hypertonicity of psoas musculature. The syndrome consists of a constellation of typically related signs and symptoms.

–**typical associated somatic dysfunctions.** As a long restrictor muscle, psoas hypertonicity is frequently associated with flexed dysfunctions of the upper lumbar, extended dysfunction of L5, and variable sacral and innominate dysfunctions. Tender points typically are found in the ipsilateral iliacus

and contralateral piriformis muscles.

–**typical gait.** Trendelenburg gait.

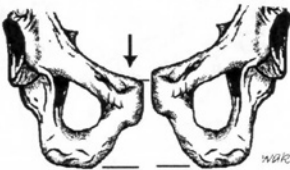
–**typical pain pattern.** Low back pain frequently accompanied by pain on the lateral aspect of the lower extremity extending no lower than the knee.

–**typical posture.** Flexion at the hip and sidebending of the lumbar spine to the side of the most hypertonic psoas muscle.

pubic bone, somatic dysfunctions of.

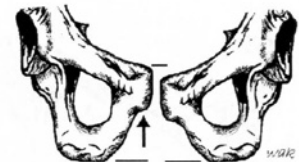
–**anterior pubic shear.** A somatic dysfunction in which one pubic bone is displaced anteriorly as compared to the normal contralateral pubic bone.

–**inferior pubic shear.** A somatic dysfunction in which one pubic bone is displaced inferiorly as compared to the normal contralateral pubic bone. (Fig. 28)



Standing flexion test = R(+)

Figure 28. Right inferior pubic shear.



Standing flexion test = R(+)

Figure 29. Right superior pubic shear.

–**posterior pubic shear.** A somatic dysfunction in which one pubic bone is displaced posteriorly as compared to the normal contralateral pubic bone.

–**superior pubic shear.** A somatic dysfunction in which one pubic bone is displaced superiorly as compared to the normal contralateral pubic bone. (Fig. 29)

pubic abduction. See pubic gapping.

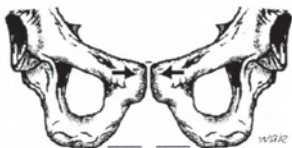pubic adduction. See pubic compression.

pubic compression. Also called pubic adduction. A somatic dysfunction in which the pubic bones are forced toward each other at the pubic symphysis. This dysfunction is characterized by tenderness to palpation over the pubic symphysis, lack of apparent asymmetry, but associated with restricted motion of the pelvic ring. (Fig. 30)

pubic gapping. Also called pubic abduction. A somatic dysfunction in which the pubic bones are pulled away from each other at the pubic symphysis. This dysfunction is frequently seen in women following childbirth. (Fig. 31)

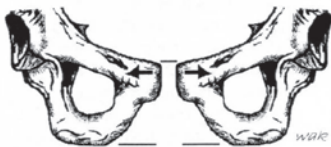pubic symphysis, somatic dysfunctions of. See pubic bone, somatic dysfunctions of.

pump handle rib motion. See rib motion, pump handle motion.



Standing flexion test = Bilaterally(+)
(False negative)

Figure 30. Pubic compression.



Standing flexion test = Bilaterally(+)
(False negative)

**Figure 31. Pubic gapping
(pubic abduction).**

R

reciprocal inhibition. The inhibition of antagonist muscles when the agonist is stimulated. See also laws, Sherrington's.

reciprocal tension membrane. The intracranial and spinal dural membrane including the falx cerebri, falx cerebelli, tentorium, and spinal dura.

red reflex. See reflex, red.

reflex. An involuntary nervous system response to a sensory input. The sum total of any particular involuntary activity. See also Chapman reflexes.

–**cephalogyric reflex.**
See reflex, oculocephalogyric.

–**cervicolumbar reflex.**
Automatic contraction of the lumbar paravertebral muscles in response to contraction of postural muscles in the neck.

–**conditioned reflex.** One that does not occur naturally in the organism or system, but that is developed by regular association of some physiological function with a related outside event.

–**myotatic reflex.** Tonic contraction of the muscles in response to a stretching force due to stimulation of muscle receptors (e.g., deep tendon reflex).

–**oculocephalogyric reflex.**
Also called oculoogyric reflex; cephalogyric reflex. Automatic

movement of the head that leads or accompanies movement of the eyes.

–**oculogyric reflex.** *See* oculocephalogyric reflex.

–**red reflex.** (1) The erythematous biochemical reaction (reactive hyperemia) of the skin in an area that has been stimulated mechanically by friction. The reflex is greater in degree and duration in an area of acute somatic dysfunction as compared to an area of chronic somatic dysfunction. It is a reflection of the segmentally related sympathicotonia commonly observed in the paraspinal area. (2) A red glow reflected from the fundus of the eye when a light is cast upon the retina.

–**somatosomatic reflex.** Localized somatic stimuli producing patterns of reflex response in segmentally related somatic structures.

–**somatovisceral reflex.** Localized somatic stimuli producing patterns of reflex response in segmentally related visceral structures.

–**viscerosomatic reflex.** Localized visceral stimuli producing patterns of reflex response in segmentally related somatic structures.

regenerative injection therapy (RIT). *See* sclerotherapy.

region. (1) An anatomical division of the body defined either by

natural, functional, or arbitrary boundaries. (2) Body areas for the diagnosis and coding of somatic dysfunction as defined in the International Classification of Diseases (At time of print, ICD-10 CM) using the codes. *See also* transitional region.

M99.00 Segmental and somatic dysfunction of head region

M99.01 Segmental and somatic dysfunction of cervical region

M99.02 Segmental and somatic dysfunction of thoracic region

M99.03 Segmental and somatic dysfunction of lumbar region

M99.04 Segmental and somatic dysfunction of sacral region

M99.05 Segmental and somatic dysfunction of pelvic region

M99.06 Segmental and somatic dysfunction of lower extremity

M99.07 Segmental and somatic dysfunction of upper extremity

M99.08 Segmental and somatic dysfunction of rib cage

M99.09 Segmental and somatic dysfunctions of abdomen and other regions

regional extension. *See* extension, regional extension.

regional motor inputs. Motion initiated by an osteopathic practitioner through body contact and vector input that produces a specific response at each segment in the mobile system.

release. The palpable change towards normalization of abnormal tissue texture, joint motion or inherent motion

perceived during or following an osteopathic manipulative treatment.

resilience. Property of returning to the former shape or size after mechanical distortion. *See also* elasticity. *See also* plasticity.

respiratory axis of the sacrum. *See* sacral motion axis, superior transverse axis.

respiratory cooperation. An osteopathic practitioner-directed inhalation and/or exhalation by the patient to assist the manipulative treatment process.

restriction. A resistance or impediment to movement.

–**joint restriction.** This term is part of the TART acronym for an osteopathic somatic dysfunction. *See* barrier (motion barrier). *See also* TART.

retrolisthesis. Posterior displacement of one vertebra relative to the one immediately below.

rib lesion. Historic term. *See* rib somatic dysfunction, of.

rib motion.

–**axis of rib motion.** An imaginary line through the costotransverse and the costovertebral articulations of the rib.

–**anteroposterior rib axis.** *See also* rib motion, bucket handle motion. (Fig. 32)

–**bucket handle motion.** Movement of the ribs during respiration such that with inhalation, the lateral aspect of the rib moves cephalad resulting in an increase of transverse diameter of the thorax. This type of rib motion is predominantly found in lower ribs, increasing in motion from the upper to the lower ribs (Fig. 33). *See also* rib motion, axis of. *See also* rib motion, pump handle.

–**caliper rib motion.** Motion of ribs 11 and 12 characterized by single joint motion; analogous to internal and external rotation.

–**exhalation rib restriction.** Involves a rib or group of ribs that first stops moving during exhalation. The key rib is the bottom rib in the group. *See also* rib somatic dysfunction, inhalation rib dysfunction.

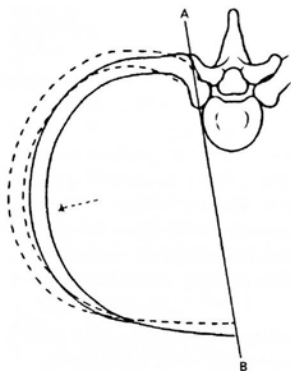


Figure 32. The functional anterior-posterior rib axis.

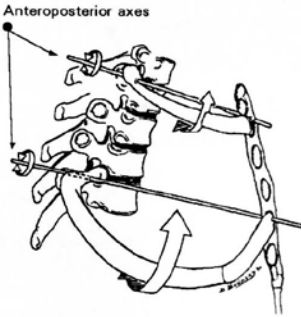


Figure 33. Bucket handle rib motion.

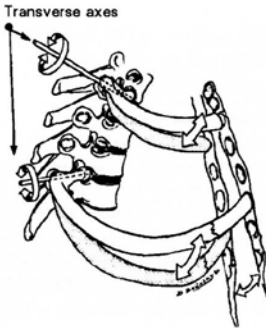


Figure 34. Pump handle rib motion.

–inhalation rib restriction.

Involves a rib or group of ribs that first stops moving during inhalation. The key rib is the top rib in the group. *See also* rib somatic dysfunction, exhalation rib dysfunction.

–pump handle motion.

Movement of the ribs during respiration such that with inhalation the anterior aspect

of the rib moves cephalad and causes an increase in the anteroposterior diameter of the thorax. This type of rib motion is found predominantly in the upper ribs, decreasing in motion from the upper to the lower ribs. (Fig. 34) *See* rib motion, axis of. *See also* rib motion, bucket handle motion.

–transverse rib axis. *See* rib motion, pump handle rib motion inhalation. *See also* rib motion, inhalation rib restriction. *See also* rib motion, exhalation rib restriction. (Fig. 35)

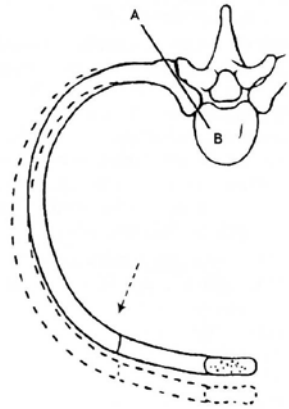


Figure 35. The functional transverse rib axis.

rib, somatic dysfunction of. A somatic dysfunction in which movement or position of one or several ribs is altered or disrupted. For example, an elevated rib is one held in a

position of inhalation such that motion toward inhalation is freer, and motion toward exhalation is restricted. A depressed rib is one held in a position of exhalation such that motion toward exhalation is freer and there is a restriction in inhalation. *See also* rib motion, inhalation rib restriction. *See also* rib motion, exhalation rib restriction.

–exhaled rib dysfunction.

(1) Somatic dysfunction characterized by a rib being held in a position of exhalation such that motion toward exhalation is more free and motion toward inhalation is restricted. Synonyms. caught in exhalation, exhalation rib dysfunction, inhalation rib restriction, depressed rib. (2) An anterior rib tender point in counterstrain. *See also* rib motion, inhalation rib restriction.

–inhaled rib dysfunction.

A somatic dysfunction characterized by a rib being held in a position of inhalation such that motion toward inhalation is more free and motion toward exhalation is restricted. Synonyms. caught in inhalation, inhalation rib dysfunction, exhalation rib restriction, elevated rib.

RIT. *See* regenerative injection therapy (RIT). *See* sclerotherapy.”

ropiness. A tissue texture abnormality characterized by a

cord-like feeling. *See also* tissue texture abnormality.

rotation. Motion about an axis.

rotation dysfunction of the sacrum. Movement of the sacrum about a vertical (y axis) usually in relation to the innominate bones. *See* sacrum, somatic dysfunctions of, rotation of sacrum.

rotation of vertebra. Movement about the anatomical vertical axis (y axis) of a vertebra; named by the motion of a midpoint on the anterior-superior surface of the vertebral body. (Fig. 36)

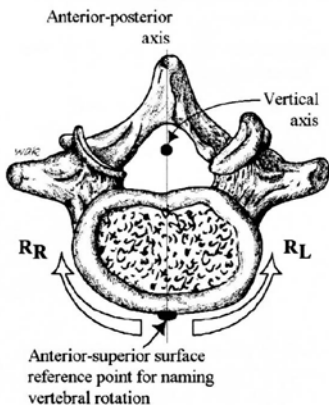


Figure 36. Rotation of a vertebra (lumbar).

rule of threes. A method to locate the approximate position of the transverse process (TP) of a thoracic segment by using the location of the spinous process (SP) of that same vertebra. The relationship is as follows:

T1 to T3, TP is at the same level as tip of the SP.

T4 to T6, TP is one half vertebral level above the tip of the SP.

T7 to T9, TP is one full vertebral level above the tip of the SP.

T10, TP is one full vertebral level above the tip of the SP.

T11, TP is one half vertebral level above the tip of the SP.

T12, TP is at the same level as tip of the SP.

S

sacral base. (1) In osteopathic palpation, the uppermost posterior portion of the sacrum. (2) The most cephalad portion of the first sacral segment.

sacral base anterior. *See* sacrum, somatic dysfunctions of, bilateral sacral flexion.

sacral base declination (unleveling). With the patient in a standing or seated position, any deviation of the sacral base from the horizontal in a coronal plane. Generally, the rotation of the sacrum about an anterior-posterior (A-P) axis.

sacral base posterior. *See* sacrum, somatic dysfunctions of, bilateral sacral extension.

sacral base unleveling. *See* sacral base declination (unleveling).

sacralization. *See* transitional vertebrae, sacralization.

sacral movement axis.

–**anterior-posterior (A-P) (x) axis.** Axis formed at the line of intersection of a sagittal and transverse plane.

–**inferior transverse axis (innominate).** (1) The hypothetical functional axis of sacral motion that passes from side to side on a line through the inferior auricular surface of the sacrum and ilia, and represents the axis for movement of the ilia on the sacrum. (2) A term described by Fred Mitchell, Sr, DO. (Fig. 37)

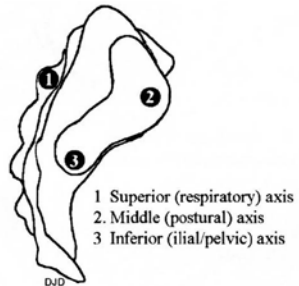


Figure 37. Sacral transverse axes (lateral view).

–**longitudinal axis.** The hypothetical axis formed at the line of intersection of the midsagittal plane and a coronal plane. *See* sacral motion axis, vertical (y) axis longitudinal. (Fig. 38)

–**middle transverse axis (postural).** (1) The hypothetical functional axis of sacral nutation/counternutation in

the standing position, passing horizontally through the anterior aspect of the sacrum at the level of the second sacral segment. (2) A term described by Fred Mitchell, Sr., DO. (Fig. 37)

–**oblique axis (diagonal).** (1) a hypothetical functional axis from the superior area of a sacroiliac articulation to the contralateral inferior sacroiliac articulation. It is designated as right or left relevant to its superior point of origin. (2) A term described by Fred Mitchell, Sr, DO. (Fig. 38)

–**postural axis.** See sacral movement axis, middle transverse axis (postural). (Fig. 37)

–**respiratory axis.** See sacral movement axis, superior transverse axis (respiratory). (Fig. 37)

–**superior transverse axis (respiratory).** (1) The hypothetical transverse axis about which the sacrum moves during the respiratory cycle. It passes from side to side through the articular processes posterior to the point of attachment of the dura at the level of the second sacral segment. Involuntary sacral motion occurs as part of the craniosacral mechanism, and is believed to occur about this axis. (2) A term described by Fred Mitchell, Sr., DO. (Fig. 37, Fig. 38)

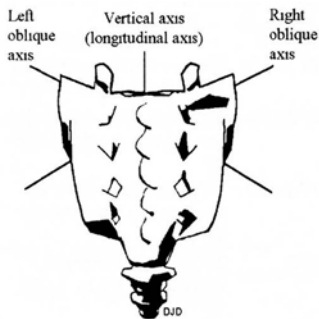


Figure 38. Axes of sacral motion (posterior view).

–**transverse (z) axes.** Axes formed by intersection of the coronal and transverse planes about which nutation/counternutation occurs. (Fig. 37)

–**vertical (y) axis (longitudinal).** The axis formed by the intersection of the sagittal and coronal planes. (Fig. 38)

sacral somatic dysfunction. See sacrum, somatic dysfunctions of.

sacral sulcus. A depression just medial to the posterior superior iliac spine (PSIS) as a result of the spatial relationship of the PSIS to the dorsal aspect of the sacrum. (Fig. 39, Fig. 40)

sacral torsion. (1) A physiologic function occurring in the sacrum during ambulation and forward bending. (2) A sacral somatic dysfunction around an oblique axis in which a torque occurs between the sacrum and

innominates. The L5 vertebra rotates in the opposite direction of the sacrum. (3) If the L5 does not rotate opposite to the sacrum, L5 is termed maladapted.

(4) Other terms for this maladaptation include, rotations about an oblique axis, anterior or posterior sacrum and a torsion with a non-compensated L5, an historic use. *See also* sacrum, somatic dysfunctions of.

sacroiliac motion. Motion of the sacrum in relationship to the innominate(s) (ilium/ ilia).

sacrum, inferior lateral angle (ILA) of. The point on the lateral surface of the sacrum where it curves medially to the body of the fifth sacral vertebrae. (Fig. 39, Fig. 40)

sacrum, somatic dysfunctions of. *See also* somatic dysfunction of sacrum.

–**anterior sacrum.** A positional term based on the Strachan model referring to sacral somatic dysfunction in which the sacral base has rotated anterior and sidebent to the side opposite the rotation. The upper limb (pole) of the SI joint has restricted motion and is named for the side on which forward rotation had occurred. Tissue texture changes are found at the deep sulcus. The motion characteristics of L5 are not described. (Fig. 41)

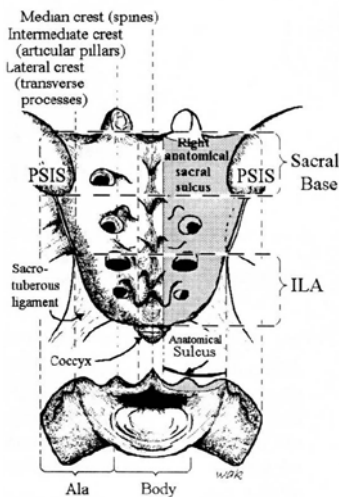


Figure 39. Anatomical sacral divisions.

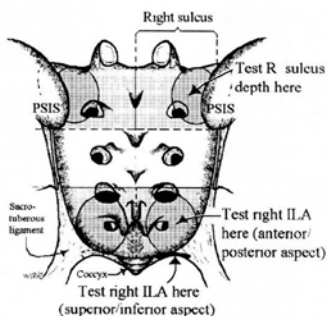


Figure 40. Clinical sacral divisions: sacral sulcus at the base, and inferior lateral angles (ILA).

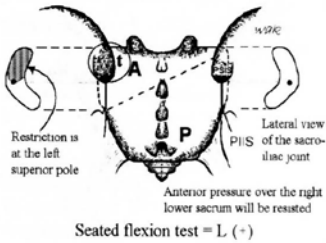


Figure 41. Anterior sacrum left. Motion of L5 is not described. There is tissue texture change (t) over the left sacral base. The superior pole of the left sacroiliac joint is affected and the left sacral base will not move posteriorly when an anterior test pressure is applied over the right lower sacrum.

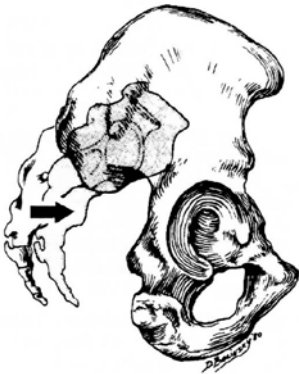

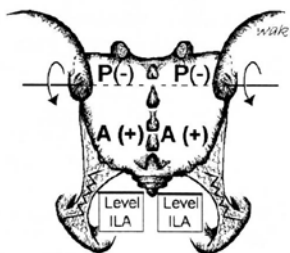
Figure 42. Anterior translated sacrum.

–anterior translated sacrum. A sacral somatic dysfunction in which the entire sacrum has moved anteriorly (forward) between the ilia. Anterior motion is freer, and the posterior motion is restricted. (Fig. 42)

–backward torsions. Also called non-neutral sacral somatic dysfunctions, an historic use. (1) A backward sacral torsion is a physiologic rotation of the sacrum around an oblique axis such that the side of the sacral base contralateral to the named axis rotates posteriorly. L5 rotates in the direction opposite to the rotation of the sacral base. (2) A term by Fred Mitchell, Sr, DO, that describes the backward torsion as being non-physiologic in terms of the walking cycle.

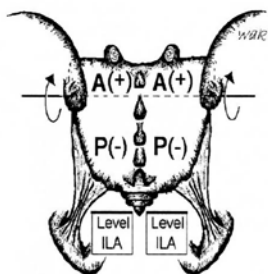
–bilateral sacral extension (sacral base posterior). (1) A sacral somatic dysfunction that involves rotation of the sacrum about a middle transverse axis such that the sacral base has moved posteriorly relative to the pelvic bones. Backward movement of the sacral base is freer, forward movement is restricted and both sulci are shallow. (2) The reverse of bilateral sacral flexion. (Fig 43)

–bilateral sacral flexion (sacral base anterior). (1) A sacral somatic dysfunction that involves rotation of the sacrum about a middle transverse axis such that the sacral base has moved anteriorly between the pelvic bones. Forward movement of the sacral base is freer, backward movement is restricted and both sulci are deep. (2) The reverse of bilateral sacral extension. (Fig 44)



Seated flexion test = Bilaterally (+)
(False negative)

Figure 43. Bilateral sacral extension.
(Sacral base posterior)



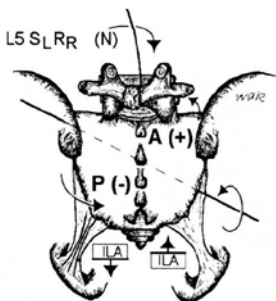
Seated flexion test = Bilaterally (+)
(False negative)

Figure 44. Bilateral sacral flexion.
(Sacral base anterior)

–**forward torsions.** Also called neutral sacral somatic dysfunctions, a historic term. (1) Forward torsion is a physiologic rotation of the sacrum around an oblique axis such that the side of the sacral base contralateral to the named axis glides anteriorly and produces a deep sulcus. L5 rotates in the direction opposite to the rotation of

the sacral base. (2) A group of somatic dysfunctions described by Fred Mitchell, Sr., DO, based on the motion cycle of walking.

–**left on left (forward) sacral torsion.** Refers to left rotation torsion around a left oblique axis. (Fig. 45) See also sacral torsion.



Seated flexion test = R(+)

Figure 45. Left on left sacral torsion. (Left on left forward torsion)

–**left on right (backward) sacral torsion.** Refers to left rotation around a right oblique axis. Findings. The left superior sacral sulcus is posterior or shallow, and the right ILA is anterior or deep. There is a positive seated flexion test on the left. L5 is non-neutral SRRR. Left superior sacral sulcus will be restricted when springing. The lumbosacral spring test is positive, and the sphinx test is positive. (Fig. 46) See sacral torsion.

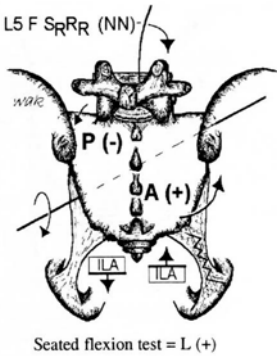


Figure 46. Left on right sacral torsion. (Left on right backward torsion)

—**posterior sacrum.** A positional term based on the Strachan model referring to a sacral somatic dysfunction in which the sacral base has rotated posterior and sidebent to the side opposite to the rotation. The dysfunction is named for the side on which the posterior rotation occurs. The tissue texture changes are found at the lower pole on the side of rotation. The motion characteristics of L5 are not described. (Fig. 47)

—**posterior translated sacrum.** A sacral somatic dysfunction in which the entire sacrum has moved posteriorly (backward) between the ilia. Posterior motion is freer, and anterior motion is restricted. (Fig. 49)

—**right on left (backward) sacral torsion.** Refers to right rotation on a left oblique axis. Findings.

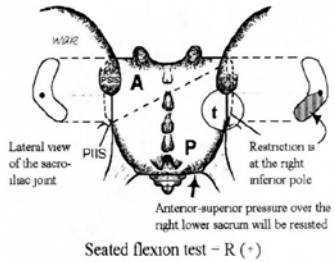


Figure 47. Posterior sacrum right. Motion of L5 is not described. There is tissue texture change (t) over the right sacroiliac joint (SI). The inferior pole of the right SI joint is affected. During motion testing, there is resistance to an anterior/superior test pressure applied over the right lower sacrum.

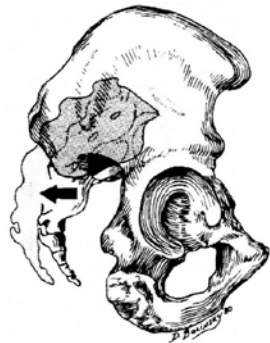

Figure 48. Posterior translated sacrum.

The right superior sacral sulcus is posterior or shallow, and the left ILA is anterior or deep. The seated flexion test is positive on the right. L5 is non- neutral SLRL. The right superior sacral sulcus is restricted when springing. The lumbosacral

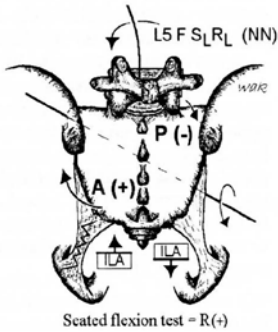


Figure 49. Right on left sacral torsion. (Right on left backward torsion.)

spring test is positive. The sphinx test is positive. (Fig. 48)
See sacral torsion

–**right on right (forward) torsion.** Refers to a right rotation about a right oblique axis. (Fig. 50)
See sacral torsion.

–**rotated dysfunction of the sacrum.** A sacral somatic dysfunction in which the sacrum has rotated about an axis approximating the longitudinal (y) axis. Motion is freer in the direction that rotation has occurred, and is restricted in the opposite direction. (Fig. 51)

–**sacral shear.** A sacral somatic dysfunction in which the sacrum appears to have slipped anteriorly or posteriorly around a transverse axis allowing it to shift within the auricular L- or C-shaped sacroiliac joint. This anterior

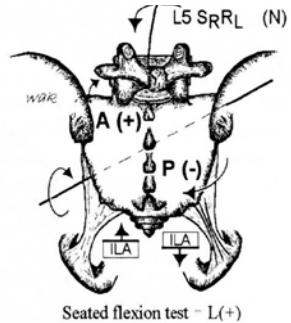


Figure 50. Right on right forward torsion.

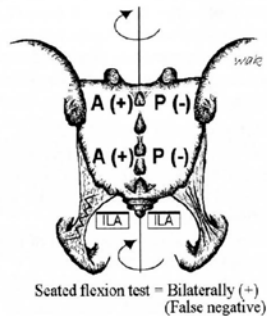

Figure 51. Right rotated dysfunction of the sacrum. (Right rotation about a vertical axis)

–unilateral sacral extension.

- (1) A sacral somatic dysfunction in which the dysfunctional side of the sacral base is posterior (the sacral sulcus of that side is shallow) in relation to the ilia and the ipsilateral ILA is anterior.
- (2) First described by Fred Mitchell, SR, DO. (Fig. 52)

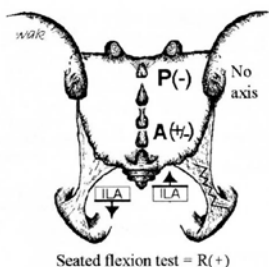


Figure 52. Right unilateral sacral extension. (Right superior sacral shear)

–unilateral sacral flexion. (1)

- A sacral somatic dysfunction in which the dysfunctional sacral base is anterior (the sacral sulcus of that side is deep) in relation to the ilia and the ipsilateral ILA is posterior.
- (2) First described by Fred Mitchell, Sr., DO. (Fig. 53)

sagittal plane. See plane, sagittal plane.

SBS. See sphenobasilar synchondrosis.

scan. An intermediate detailed examination of specific body regions that have been identified

by findings emerging from the initial examination.

scaphocephaly. Also called scaphoid head or hatchet head. It is a transverse compression of the cranium with a resultant mid-sagittal ridge.

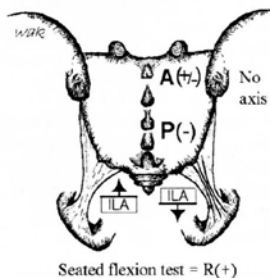


Figure 53. Right unilateral sacral flexion. (Right inferior sacral shear)

scaphoid head. See also scaphocephaly.

sclerotherapy. (1) Treatment involving injection of a proliferant solution at the osseous-ligamentous junction. (2) Treatment involving injection of irritating substances into weakened connective tissue areas such as fascia, varicose veins, hemorrhoids, esophageal varices, or weakened ligaments. The intended body's response to the irritant is fibrous proliferation with shortening/ strengthening of the tissues injected.

sclerotome. (1) The pattern of innervation of structures derived from embryonal mesenchyme (joint capsule, ligament and bone). (2) The area of bone innervated by a single spinal segment. (3) The group of mesenchymal cells emerging from the ventromedial part of a mesodermal somite and migrating toward the notochord. Sclerotomal cells from adjacent somites become merged in intersomatically located masses that are the primordia of the centra of the vertebrae. (Fig. 54)

sclerotomal pain. Deep, dull achy pain associated with tissues derived from a common sclerotome. (Fig. 54)

scoliosis. (1) Pathological or functional lateral curvature of the spine. (2) An appreciable lateral deviation in the normally straight vertical line of the spine. (Fig. 55)

screen. The initial general somatic examination to determine signs of somatic dysfunction in various regions of the body. *See also* scan.

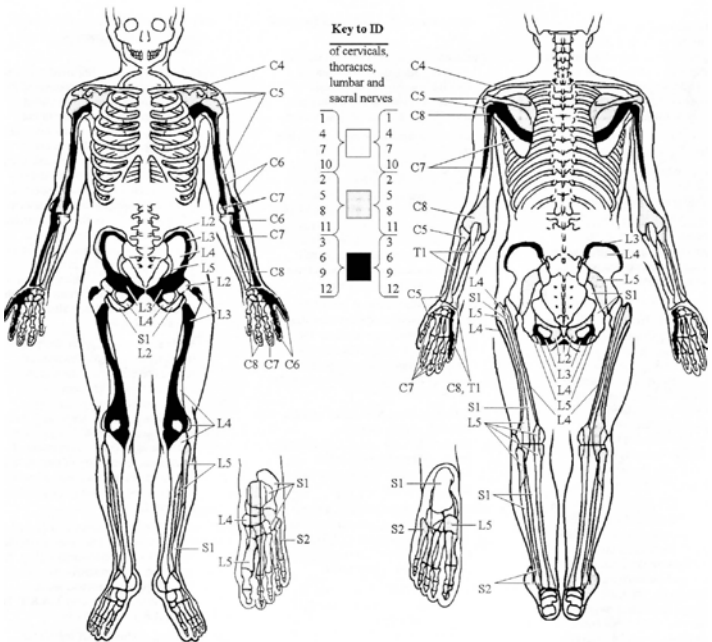


Figure 54. Anterior and posterior sclerotomal innervations. (Modified from *Foundations for Osteopathic Medicine*, Ward RC—Ed., Williams & Wilkins; 1997:644).

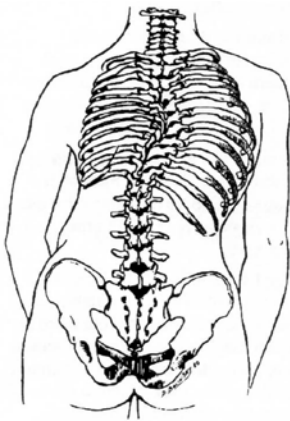


Figure 55. Scoliosis.

secondary joint motion. Also called accessory joint motion. Involuntary or passive motion of a joint.

segment. (1) A portion of a larger body or structure set off by natural or arbitrarily established boundaries, often equated with spinal segment. (2) To describe a single vertebra or a vertebral segment corresponding to the sites of origin of rootlets of individual spinal nerves. (3) A portion of the spinal cord.

segmental diagnosis. The final stage of the spinal somatic examination in which the nature of the somatic dysfunction is detailed at a segmental level. See also scan. See also screen.

segmental dysfunction.

Dysfunction in a mobile system located at explicit segmental mobile units. Palpable characteristics of a dysfunctional segment are those associated with somatic dysfunction. Responses to regional motor inputs at the dysfunctional segment support the concepts of complete motor asymmetry and mirror-image motion asymmetries. See also STAR. See also TART.

segmental mobile unit. A unit of the human movement system consisting of a bone, with articular surfaces for movement, as well as the adnexal tissues that create movement, allow movement and establish position under motor control.

segmental motion. Movement within a vertebral unit described by central nervous system (CNS) response to repeated sensory stimulation that generally follows habituation.

sensitization. Hypothetically, a short-lived (minutes or hours) increase in central nervous system (CNS) response to repeated sensory stimulation that generally follows habituation.

shear. An action or force causing or tending to cause two contiguous parts of an articulation to slide relative to each other in a direction parallel to their plane of contact. See also pubic bone, somatic dysfunctions of. See also innominates,

somatic dysfunctions of, inferior innominate shear. *See also* innominates, somatic dysfunction of, superior innominate shear. *See also* sacrum, somatic dysfunctions of, sacral shear.

Sherrington law. *See* law, Sherrington.

sidebent. The position of any one or several vertebral bodies after sidebending has occurred. (Fig 56) *See also* sidebending

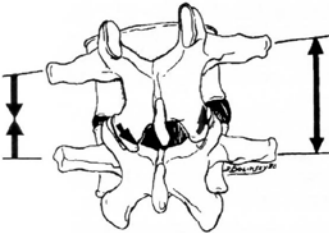

Figure 56. Sidebent.

sidebending. *Also called* lateral flexion, lateroflexion, or flexion right (or left). Movement in a coronal (frontal) plane about an anterior-posterior (x) axis.

skin drag. Sense of resistance to light traction applied to the skin. Related to the degree of moisture and degree of sympathetic nervous system activity.

soft tissue (ST). *See* osteopathic manipulative treatment, soft tissue method.

soft tissue technique. *See* osteopathic manipulative treatment, soft tissue method.

somatic dysfunction. Impaired or altered function of related components of the body framework system: skeletal, arthroal and myofascial structures, and their related vascular, lymphatic and neural elements. It is characterized by positional asymmetry, restricted range of motion, tissue texture abnormalities, and/or tenderness. The positional and motion aspects of somatic dysfunction are generally described by: (1) The position of a body part as determined by palpation and referenced to its defined adjacent structure, (2) The directions in which motion is freer, and (3) The directions in which motion is restricted. Somatic dysfunction is treatable using osteopathic manipulative treatment.

–acute somatic dysfunction. Impairment or altered function of related components of the body framework system that is characterized in early stages by one or more of the following: pain, erythema, a palpable sense of relative warmth, moisture and boggy texture, vasodilation, edema, tenderness, and tissue contraction. Identified by TART. *See also* TART.

–chronic somatic dysfunction. Impairment or altered function of long standing duration of related components of the body framework system characterized by one or more

of the following: itching, paresthesias, a palpable sense of tissue dryness, coolness, tissue contracture, fibrosis, tenderness and pallor.

somatic dysfunction of.

–**pubic bone.** *See* pubic bone, somatic dysfunctions of.

–**pubic symphysis.** *See* pubic bone, somatic dysfunctions of.

–**sacrum.** *See* sacrum, somatic dysfunctions of

–**abdominal.** A somatic dysfunction of abdomen and other regions.

–**cranial.** A somatic dysfunction of the head and the occipito-atlantal region.

–**cervical.** A somatic dysfunction of the cervical region and the cervicothoracic region.

–**innominate.** A somatic dysfunction of lower.

–**lower extremity.** A somatic dysfunction of lower extremity region.

–**lumbar.** A somatic dysfunction of the lumbar region and lumbosacral region.

–**pelvic.** A somatic dysfunction of pelvic (iliosacral) region, pubic region and hip region, glenohumeral, sternoclavicular and scapulothoracic region.

–**rib.** A somatic dysfunction of rib cage, costochondral, costovertebral, sternal and sternochondral regions.

–**sacral.** A somatic dysfunction of the sacral region, sacroiliac joint and sacrococcygeal region.

–**thoracic.** A somatic dysfunction of the thoracic region and thoracolumbar region.

–**upper extremity.** A somatic dysfunction of upper extremity region, acromioclavicular.

–**primary somatic dysfunction.** (1) The initial or first somatic dysfunction to appear temporally. (2) The somatic dysfunction that maintains a total pattern of dysfunction, including other secondary.

–**secondary somatic dysfunction.** (1) Somatic dysfunction arising in response from a primary somatic dysfunction. (2) Somatic dysfunction arising as a consequence of other etiology.

–**type I somatic dysfunction.** A group dysfunction of the thoracic and lumbar vertebrae. These vertebrae are neutral relative to the sagittal plane and demonstrate a preference for sidebending and rotation in opposite directions, (e.g. sidebent right and rotated left or sidebent left and rotated right).

–**type II somatic dysfunction.** A single segmental dysfunction of the thoracic or lumbar vertebrae. This vertebra is significantly flexed or extended and demonstrates a preference

for sidebending and rotation in the same direction (e.g. rotated right and sidebent right or sidebent left, rotated left).

somatogenic. That which is produced by activity, reaction and change originating in the musculoskeletal system.

somatosomatic reflex. See reflex, somatosomatic reflex.

somatovisceral reflex. See reflex, somatovisceral reflex.

spasm. A sudden, violent, involuntary contraction of a muscle or group of muscles, attended by pain and interference with function, producing involuntary movement and distortion (compare with hypertonicity). (*Dorland's*).

Spencer technique. See osteopathic manipulative treatment, Spencer technique.

sphenobasilar synchondrosis (SBS). Also called sphenobasilar symphysis. The cartilaginous junction between the basilar portion of the sphenoid and the basilar portion of the occiput.

–somatic dysfunctions of SBS.

Any of a group of somatic dysfunctions involving primarily the inter-relationship between the basilar portion of the sphenoid (basisphenoid) and the basilar portion of the occiput (basiocciput).

– **SBS compression.** Somatic dysfunction in which the basisphenoid and basiocciput

are held forced together significantly limiting SBS motion.

– **SBS extension.** Sphenoid and occiput have rotated in opposite directions around parallel transverse axes; the basiocciput and basisphenoid are both inferior in SBS extension with a decrease in the dorsal convexity between these two bones. (Fig. 57)

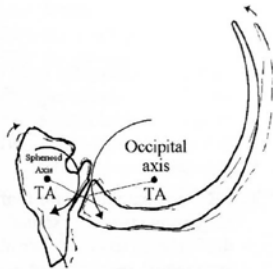


Figure 57. Extension (SBS).

– **SBS flexion.** Sphenoid and occiput have rotated in opposite directions around parallel transverse axes; the basiocciput and basisphenoid are both superior in SBS flexion with an increase in the dorsal convexity between these two bones. (Fig. 58)

– **lateral strain.** Sphenoid and occiput have rotated in the same direction around parallel vertical axes. Lateral strains of the SBS are named for the position of the basisphenoid, right or left. (Fig. 59)

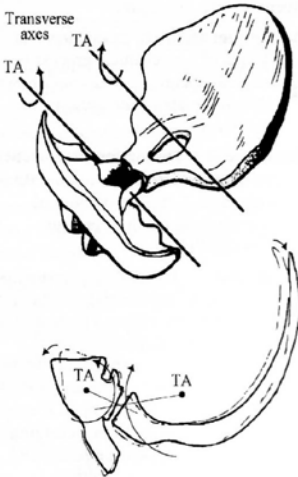

Figure 58. Flexion (SBS).

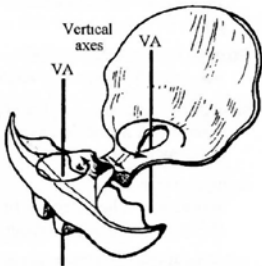


Figure 59. Right lateral strain (SBS).

-sidebending-rotation. Sphenoid and occiput have rotated in opposite directions around parallel vertical axes and rotate in the same direction around an anterior-posterior (A-P) axis. SBS

sidebending-rotations are named for the convexity, right or left. (Fig. 60)

-torsion. Sphenoid and occiput have rotated in opposite directions around an anterior-posterior (A-P) axis. SBS torsions are named for the high greater wing of the sphenoid, right or left. (Fig. 61)

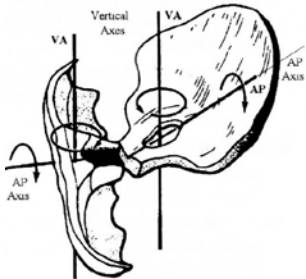


Figure 60. Left sidebending/rotation (SBS).

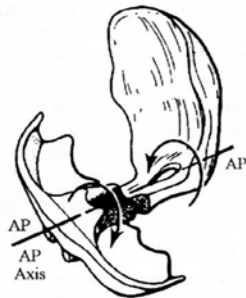


Figure 61. Right torsion (SBS).

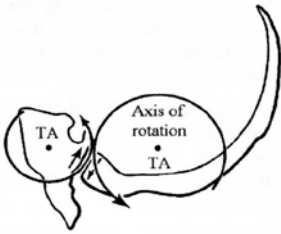


Figure 62. Superior vertical strain (SBS).

–**vertical strain.** Sphenoid and occiput have rotated in the same direction around parallel transverse axes. Vertical strains of the SBS are named for the position of the basisphenoid, superior or inferior. (Fig. 62)

sphenobasilar symphysis (SBS). See sphenobasilar synchondrosis

spinal facilitation. (1) The maintenance of a pool of neurons (e.g., premotor neurons, motor neurons or preganglionic sympathetic neurons in one or more segments of the spinal cord) in a state of partial or subthreshold excitation; in this state, less afferent stimulation is required to trigger the discharge of impulses. (2) A theory regarding the neurophysiological mechanisms underlying the neuronal activity associated with somatic dysfunction. (3) Facilitation may be due to sustained increase in afferent input, aberrant patterns of afferent input, or changes within

the affected neurons themselves or their chemical environment. Once established, facilitation can be sustained by normal central nervous system (CNS) activity.

splenic pump technique. See osteopathic manipulative treatment, splenic pump technique.

spontaneous release by positioning. See osteopathic manipulative treatment, counterstrain.

sprain. Stretching injuries of ligamentous tissue (compare with strain).

–**first degree.** Microtrauma.

–**second degree.** Partial tear.

–**third degree.** Complete disruption.

springing technique. See osteopathic manipulative treatment, springing technique; osteopathic manipulative treatment, articularity.

sphinx test. See backward bending test.

spring test. (1) A test used to differentiate between backward or forward sacral torsions/rotations. (2) A test used to differentiate bilateral sacral extension and bilateral sacral flexion. (3) A test used to differentiate unilateral sacral extension and unilateral sacral flexion. See also lumbosacral

spring test.

STAR. A mnemonic for four diagnostic criteria of somatic dysfunction: sensitivity changes, tissue texture abnormality, asymmetry and alteration of the quality and quantity of range of motion.

static contraction. *See* contraction, isometric contraction.

Still, MD, DO, Andrew Taylor.

Founder of osteopathic medicine; 1828-1917. First announced the tenets of osteopathic medicine on June 22, 1874, established the American School of Osteopathy in 1892 at Kirksville, MO.

still point. (1) A term used to identify and describe the temporary cessation of the rhythmic motion of the primary respiratory mechanism. It may occur during osteopathic manipulative treatment when a point of balanced membranous or ligamentous tension is achieved. (2) A term used by William G. Sutherland, DO.

Still Technique. *See* osteopathic manipulative treatment, Still Technique.

strain. (1) Stretching injuries of muscle tissue. (2) Distortion with deformation of tissue. *See also* ligamentous strain.

strain-counterstrain. *See* osteopathic manipulative treatment, counterstrain.

Strachan model. *See* sacrum, somatic dysfunctions of, anterior sacrum. *See also* sacrum, somatic dysfunctions of, posterior sacrum.

stretching. Separation of the origin and insertion of a muscle and/or attachments of fascia and ligaments.

stringiness. A palpable tissue texture abnormality characterized by fine or string like myofascial structures.

structural examination. *See* osteopathic structural examination.

subluxation. (1) A partial or incomplete dislocation. (2) A term describing an abnormal anatomical position of a joint which exceeds the normal physiologic limit, but does not exceed the joint's anatomical limit.

superior (upslipped) innominate. *See* innominate, somatic dysfunctions of, superior innominate shear.

superior pubic shear. *See* pubic bone, somatic dysfunctions of. *See also* symphyseal shear. (Fig. 31)

superior transverse axis. *See* sacral motion axis, superior transverse axis (respiratory); sacral motion axis, transverse (z) axis.

supination. (1) Beginning in anatomical position, applied to the hand, the act of turning

the palm forward (anteriorly) or upward, performed by lateral external rotation of the forearm. (2) Applied to the foot, it generally applies to movements (adduction and inversion) resulting in raising of the medial margin of the foot, hence of the longitudinal arch. A compound motion of plantar flexion, adduction and inversion. *See also* pronation.

supine. Lying with the face upward.

symmetry. The similar arrangement in form and relationships of parts around a common axis, or on each side of a plane of the body.

Sutherland fulcrum. A shifting suspension fulcrum of the reciprocal tension membrane located along the straight sinus at the junction of the falx cerebri and tentorium cerebelli. *See also* reciprocal tension membrane; osteopathic manipulative treatment, osteopathic cranial manipulative medicine (OCMM).

symphyseal shear. The result of an action or force causing or tending to cause the two parts of the symphysis to slide relative to each other in a direction parallel to their plane of contact. It is usually found in an inferior/superior direction but is occasionally found to be in an anterior/posterior direction. (Fig. 28, Fig. 31)

T

tapotement. Striking the belly of a muscle with the hypothenar edge of the open hand in rapid succession in an attempt to increase its tone and arterial perfusion.

TART. A mnemonic for four diagnostic criteria of somatic dysfunction: tissue texture abnormality, asymmetry, restriction of motion, and tenderness.

technique. Methods, procedures, and details of a mechanical process or surgical operation. *See also* osteopathic manipulative treatment.

tenderness. (1) Discomfort or pain elicited by an osteopathic practitioner through palpation. (2) A state of heightened sensitivity to touch or pressure.

tender points. Small, hypersensitive points in the myofascial tissues of the body that do not have a pattern of pain radiation. These points are a manifestation of somatic dysfunction and are used as diagnostic criteria and for monitoring treatment. *See also* tenderpoints. *See also* trigger point.

tenderpoints. A system of myofascial tender points used for the counterstrain system for the diagnosis and treatment of somatic dysfunction originally

thoracic aperture (superior)

described by Lawrence Jones, DO, FAAO. *See also* osteopathic manipulative treatment, counterstrain.

thoracic aperture (superior). *See* thoracic inlet.

thoracic inlet. (1) The functional thoracic inlet consists of T1-4 vertebrae, ribs 1 and 2 plus their costal cartilages, and the manubrium of the sternum. (2) The anatomical thoracic inlet consists of T1 vertebra, the first ribs and their costal cartilages, and the superior end of the manubrium. *See* fascial patterns.

thoracic pump. *See* osteopathic manipulative treatment, thoracic pump technique.

thrust technique. *See* osteopathic manipulative treatment, thrust technique. *See also* osteopathic manipulative treatment, high velocity low amplitude technique (HVLA).

tissue texture abnormality (TTA). A palpable change in the tissues of the body away from their normal state. Common findings include: boggy, thickness, ropiness, stringiness, firmness, and changes in temperature or moisture. This term is part of the “TART” acronym for the diagnostic criteria of somatic dysfunction. *See also* TART.

tonus. A normal physiologic state in which there is a slight continuous tension of muscle tissue, which in skeletal muscles,

aids in the maintenance of posture and facilitates a response to stimulation.

torsion. A motion or state where one end of a part is twisted about a longitudinal axis while the opposite end is held fast or turned in the opposite direction.

torsion, sacral. *See* sacral torsion. *See also* sacrum, somatic dysfunctions of.

torsion, sphenobasilar synchondrosis. A physiologic motion pattern about an anteroposterior axis of the sphenobasilar symphysis/synchondrosis. *See also* sphenobasilar synchondrosis (SBS), torsion.

traction. A linear force acting to draw structures apart.

traction technique. *See* osteopathic manipulative treatment, traction technique.

transitional region. Areas of the axial skeleton where structure changes significantly lead to functional changes; transitional areas commonly include the following:

–**occipitocervical region (OA).** Typically the OA-AA-C2 region is described.

–**cervicothoracic region (CT).** Typically C7-T(1)

–**thoracolumbar region (TL).** Typically T10-L(1)

–**lumbosacral region (LS).** Typically L5-S(1)

transitional vertebrae. A congenital anomaly of a vertebra in which it develops characteristic(s) of the adjoining structure or region.

–**lumbarization.** A transitional segment in which the first sacral segment becomes like an additional lumbar vertebra articulating with the second sacral segment.

–**sacralization.** (1) Incomplete separation and differentiation of the fifth lumbar vertebra (L5) such that it takes on characteristics of a sacral vertebra. (2) When transverse processes of the fifth lumbar (L5) are atypically large, causing pseudoarthrosis with the sacrum and/or ilia(um), referred to as batwing deformity, if bilateral.

translation. Motion along an axis.

translatory motion. See motion, translatory motion.

transverse axis of sacrum. See sacral, sacral movement axis, transverse (z) axis. (Fig. 37)

transverse process. Projects laterally from the region of each pedicle. The pedicle connects the posterior elements to the vertebral body. (Fig. 63)

transverse rib axis. See also rib motion, pump handle rib motion. (Fig. 34)

Traube-Herring-Mayer wave. An oscillation that has been measured in association with blood pressure, heart rate, cardiac contractility, pulmonary blood flow, cerebral blood flow and movement of the cerebrospinal fluid, and peripheral blood flow including venous volume and thermal regulation. This whole-body phenomenon, which

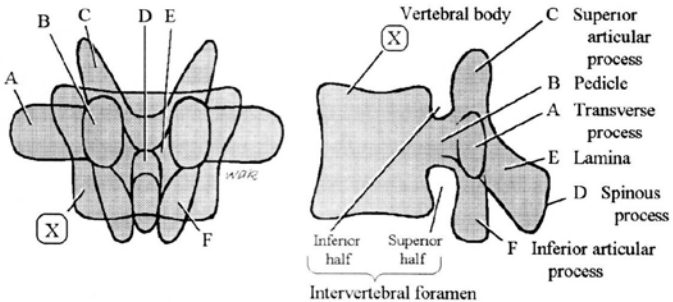


Figure 63. The pedicle (B) is the key structure from which other vertebral parts can be identified. (Ward RC, Ex. Ed., *Foundations for Osteopathic Medicine*, Second Edition, Lippincott Williams & Wilkins, Philadelphia, 2003:730.)

exhibits a rate typically slightly less than and independent of respiration, bears a striking resemblance to the primary respiratory mechanism.

Travell trigger point. *See* trigger point.

treatment, active. A historical term. *See* osteopathic manipulative treatment, active method.

treatment, osteopathic manipulative techniques. *See* osteopathic manipulative treatment.

Trendelenburg test. The patient, with back to the examiner, is told to lift first one foot and then the other. The position and movements of the gluteal fold are watched. When standing on the affected limb the gluteal fold on the sound side falls instead of rising. Seen in poliomyelitis, un-united fracture of the femoral neck, coxa vara and congenital dislocations.

trigger point (myofascial trigger point). (1) A small hypersensitive site that, when stimulated, consistently produces a reflex mechanism that gives rise to referred pain and/or other manifestations in a consistent reference zone that is consistent from person to person. (2) These points were most extensively and systematically documented. by Janet Travell, MD, and David Simons, MD.

trophic. Pertaining to nutrition, especially in the cellular environment (e.g., trophic function — a nutritional function).

trophicity. (1) A nutritional function or relation. (2) The natural tendency to replenish the body stores that have been depleted.

trophotropic. Concerned with or pertaining to the natural tendency for maintenance and/or restoration of nutritional stores.

tropic. A word termination denoting turning toward, changing or tendency to change.

tropism, facet. Unequal size and/or facing of the zygapophyseal joints of a vertebra. *See also* facet asymmetry.

type I somatic dysfunction. *See* somatic dysfunction, type I somatic dysfunction. *See also* physiologic motion of the spine.

type II somatic dysfunction. *See* somatic dysfunction, type II somatic dysfunction. *See also* physiologic motion of the spine.

U

uncommon compensatory pattern. *See* fascial patterns, uncommon compensatory pattern.

uncompensated fascial pattern. *See* fascial patterns, uncompensated fascial pattern.

V

v-spread. *See* osteopathic manipulative treatment, v-spread.

velocity. The instantaneous rate of motion in a given direction.

ventral technique. *See* osteopathic manipulative treatment, visceral manipulation.

vertebral unit. Two adjacent vertebrae with their associated intervertebral disk, arthrodial, ligamentous, muscular, vascular, lymphatic and neural elements. (Fig. 64)

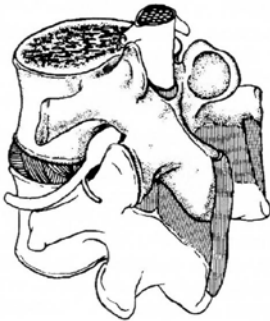

Figure 64. Vertebral unit.

vertical axis. *See* sacral motion axis, vertical (y) axis (longitudinal).

visceral dysfunction. Impaired or altered mobility or motility of the visceral system and related fascial, neurological, vascular, skeletal and lymphatic elements.

visceral manipulation. *See* osteopathic manipulative treatment, visceral manipulation.

viscerosomatic dysfunction. Somatic dysfunction related to a viscerosomatic reflex. *See* reflex, viscerosomatic.

viscerosomatic reflex. *See* reflex, viscerosomatic reflex.

viscerovisceral reflex: *See* reflex, viscerovisceral reflex.

viscosity. (1) A measurement of the rate of deformation of any material under load. (2) The capability possessed by a solid of yielding continually under stress. *See also* elasticity; plasticity.

W

weight-bearing line of L3. *See* gravitational line. (Fig. 16)

Abbreviations

AA	atlanto-axial
AACOM	American Association of Colleges of Osteopathic Medicine
AOA	American Osteopathic Association
AOBNMM	American Osteopathic Board of Neuromusculoskeletal Medicine
A-P	anterior-posterior
ART	articulatory
AIIS	anterior inferior iliac spines
ASIS	anterior superior iliac spines
BLT	balanced ligamentous tension
BMT	balanced membranous tension
C-NMM/ OMM	Certification in Neuromusculoskeletal Medicine/ Osteopathic Manipulative Medicine
C	cervical
CCP	common compensatory pattern
CNS	central nervous system
CO	coccygeal
COCA	Association Commission on Osteopathic College Accreditation
CR	cranial
CRI	cranial rhythmic impulse

Abbreviations

CS	counterstrain treatment
CT	cervico-thoracic
CV-4	compression of the 4th ventricle technique
D	direct treatment
DIR	direct treatment
DO	Doctor of Osteopathic Medicine or Diplomat in Osteopathy
E	extended
ECOP	Educational Council on Osteopathic Principles
ERS	extended/rotated/sidebent
F	flexed
FAAO	Fellow of the American Academy of Osteopathy
FOR	facilitated oscillatory release treatment
FPR	facilitated positional release treatment
FRS	flexed/rotated/sidebent
HVLA	high velocity low amplitude treatment
I	indirect treatment
ILA	inferior lateral angle
IND	indirect treatment
I/IND	indirect method
INR	integrated neuromusculoskeletal release treatment
JTP	Jones tenderpoint
L	left or lumbar
LAS	ligamentous articular strain treatment
LS	lumbo-sacral
ME	muscle energy treatment
MFR	myofascial release treatment
MTrP	myofascial trigger point
N	neutral

NMM-OMM	neuromusculoskeletal medicine-osteopathic manipulative medicine
NRS	neutral/rotated/sidebent
OA	occipito-atlantal
OCF	osteopathy in the cranial field (historical)
OCMM	osteopathic cranial manipulative medicine
OMM	osteopathic manipulative medicine
OMT	osteopathic manipulative treatment
OMTh	osteopathic manipulative therapy
ONMM	osteopathic neuromusculoskeletal medicine
OPP	osteopathic principles and practice
PINS	progressive inhibition of neuromuscular structures
PSIS	posterior superior iliac spines
R	right or rotated or rib
RIT	regenerative injection therapy
S	sidebent or sacrum
SBS	sphenobasilar synchondrosis
SD	somatic dysfunction
ST	soft tissue
STAR	sensitivity / tissue texture changes/ asymmetry / restriction of motion
T	thoracic
TART	tenderness / asymmetry / restriction of motion / tissue texture change
TL	thoraco-lumbar
TP	tenderpoint
TrP	Travell trigger point
TTA	tissue texture abnormality
VIS	visceral manipulative treatment

Dorland, W A Newman. *Dorland's illustrated medical dictionary. 31st ed.* Philadelphia, PA : Saunders; 2007

About AACOM

Mission

The American Association of Colleges of Osteopathic Medicine (AACOM) provides leadership for the osteopathic medical education community by promoting excellence in medical education, research and service, and by fostering innovation and quality across the continuum of osteopathic medical education to improve the health of the American public.

Vision

AACOM is recognized as the international leader of osteopathic medical education (OME) and an international leader of medical education. Through the colleges of osteopathic medicine and its Councils, AACOM coordinates the role of OME in the U.S. health care system and promotes and fosters excellence throughout medical education.

Osteopathic medical education develops physicians through a continuum of education that is based upon osteopathic philosophy and practice and the training of physicians who are highly qualified in the knowledge, skills, and temperament to lead and participate in the delivery of health care in the 21st Century. OME consists of knowledge-based learning communities that are innovative in their advanced use of technology for collaboration, communication and the delivery of outcome-based curriculum. AACOM supports the use of an open electronic forum for facilitating communication and knowledge management. By promoting community-oriented and learner-centered medical education, and a preventive medicine perspective, osteopathic medical education programs train physicians to provide high-quality health care to meet the public's changing health care needs.

AACOM is positioned to assume a leadership role in promoting continuous quality improvement of osteopathic medical education. AACOM facilitates the development of medical educators and administrators. It is internationally recognized as a primary resource for innovative teaching techniques and methodologies; for advances in curriculum design and evaluation strategies; for enhanced teaching tools; and for highlighting best practices in the delivery of education in Osteopathic Principles and Practice. It promotes and facilitates clinical, basic science, health care services, and medical education research and its dissemination, promotes the training of researchers, and identifies sources of research and other grant and contract funding. AACOM sponsors internationally recognized meetings on osteopathic medical education and research.

The AACOM office is the national leader in the processing of applications for colleges of osteopathic medicine, and in enhancing the OME applicant pool. AACOM maintains collaborative relationships with other organizations that serve a complementary purpose. AACOM is recognized as the primary source of useful data concerning OME and facilitates data-based decision making. It is the major resource of OME information and analysis for government policymakers and other entities, and an advocate on behalf of the colleges of osteopathic medicine.

aacom[®]

AMERICAN ASSOCIATION OF
COLLEGES OF OSTEOPATHIC MEDICINE

5550 Friendship Blvd., Suite 310
Chevy Chase, MD 20815-7231
www.aacom.org

